Surveillance par Imagerie et Haut Risque Familial Quand ? Comment ?

Anne Tardivon
et le Service de Radiologie
Institut Curie, Site Paris

- Quand ?
- Comment ?
- Ce que l'on ne sait pas ?

Quand ?

FILTRE des consultations oncogénétiques +++

- Femmes porteuses d'une mutation
  - A partir de 30 ans
    - Avant, discussion au cas par cas (p53)
  - Rythme annuel
    - IRM, mammographie ± échographie
- Tests génétiques négatifs (le + fréquent)
  - Ajout ou non de l'IRM selon le niveau de probabilité
  - Modèle de Claus ≥ 40% => RA cumulé ≥ 30%

Comment ?

- INFORMATION des patientes
  - Faux positifs isolés de l'IRM
  - 1er tour autour de 15%
  - Tours suivants : <10% (recommandations EUSOMA)

Chronologie des Examens d'Imagerie

IRM
2ème semaine du cycle
Indiquer DDR dans CR

↓

Imagerie Standard
Mammographie
± Echographie

COMMENTAIRES

- Débuter par la technique la plus SENSIBLE

-Avantage: En cas d'IRM +, l'imagerie standard est d'emblée CIBLEE

- La Mammographie est INDISPENSABLE
  - risque de faux négatifs dans CCIS
  - « Bruit de fond » glandulaire
  - Femmes <35 ans: 1 obl Externe/sein

-Pas de valeur ajoutée de l'écho si IRM normale

- Echographie systématique si CI à l'IRM

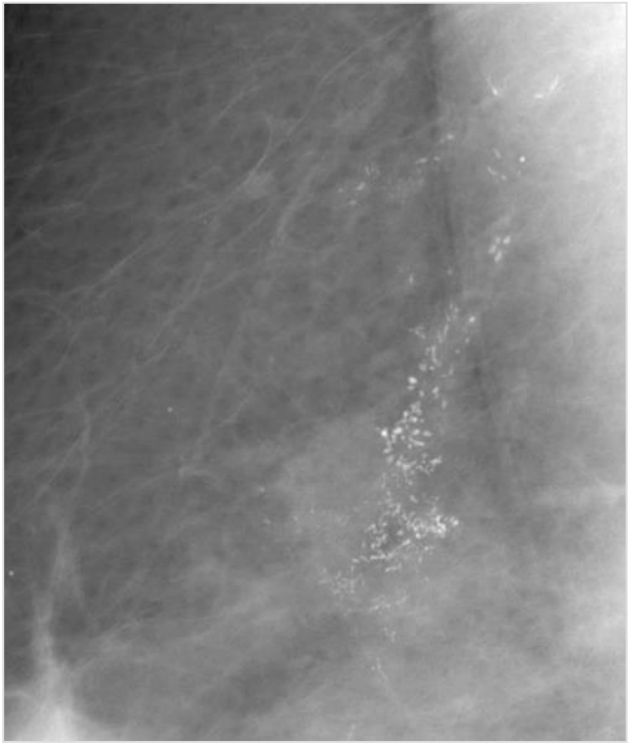

CCIS, Haut Grade

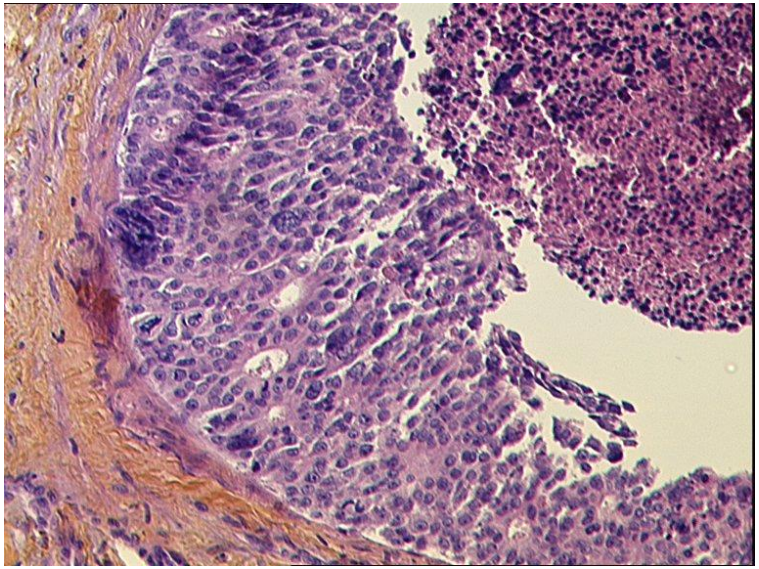

CCIS	Warner	Kuhl	Pays-Bas	MARIBS
Nbre	27%	22%	12%	17%
IRM	67%	89%	17%	33%
Mammo	50%	33%	83%	83%

IRM
2ème semaine du cycle

↓

Imagerie Standard
Mammographie
± Echographie

↓

Compte- Rendu
de SYNTHESE
avec en cas d'anomalie
Une CAT claire et précise

COMMENTAIRES

Il est SOUHAITABLE que:

-l'ensemble des examens soit réalisé par une MEME équipe

-le circuit de biopsies sous IRM soit organisé (si non réalisées sur site)

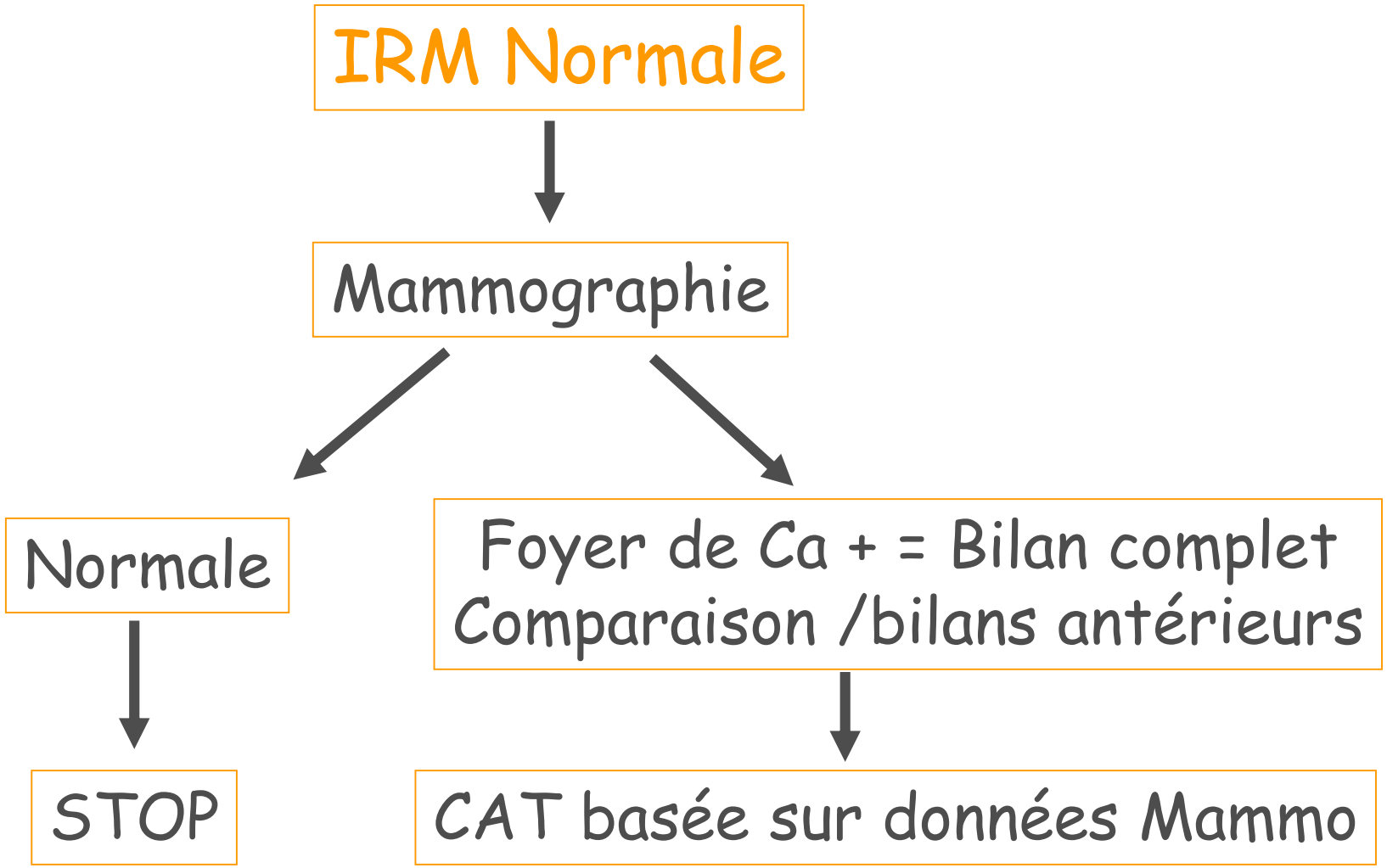

* Si échographie réalisée, augmenter son seuil de positivité

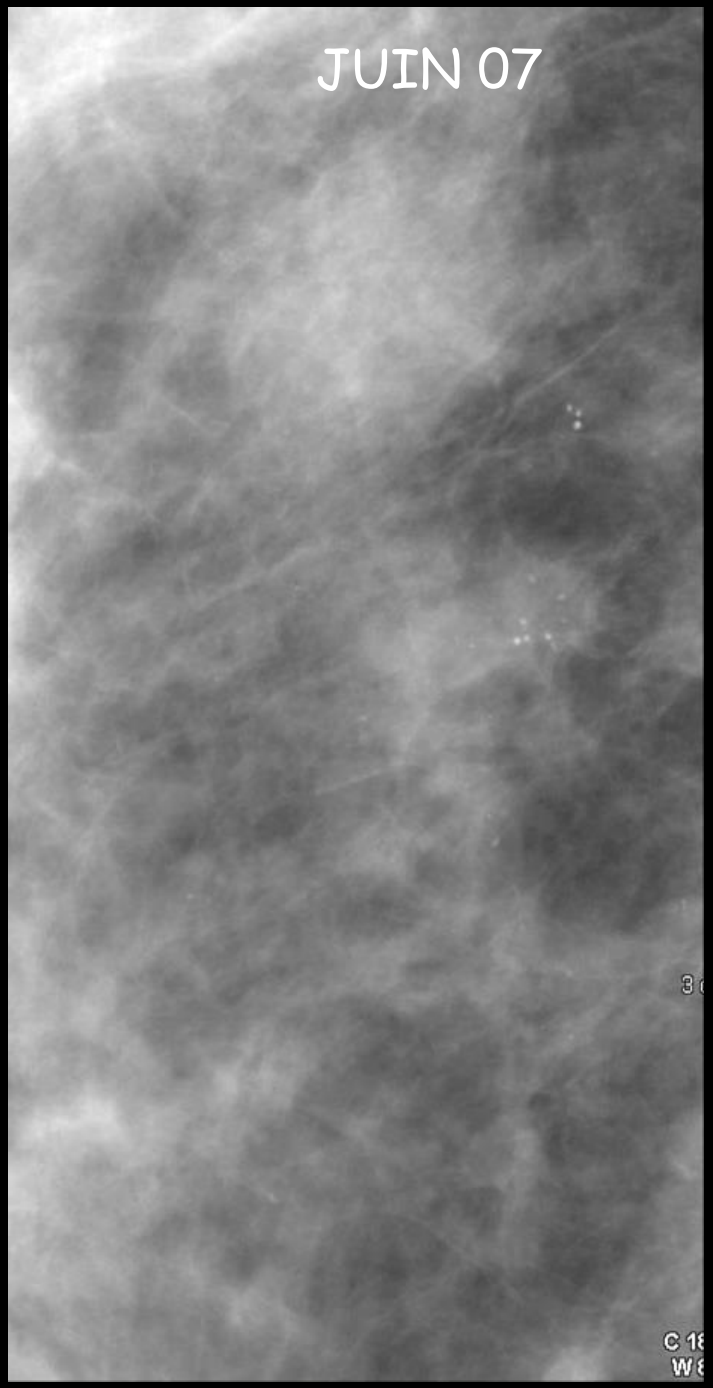

Mutation *BRCA2*

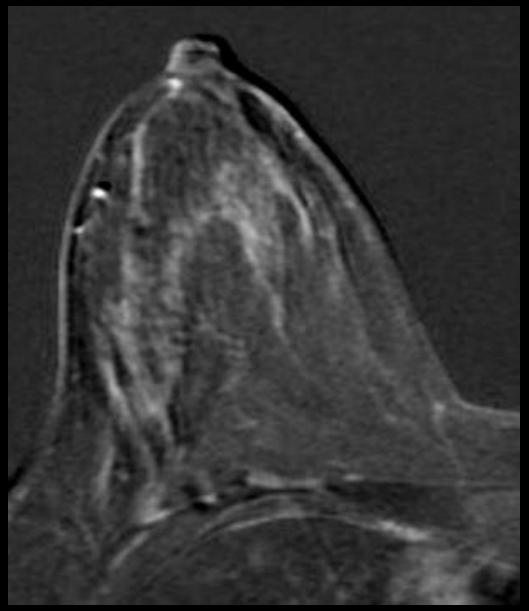

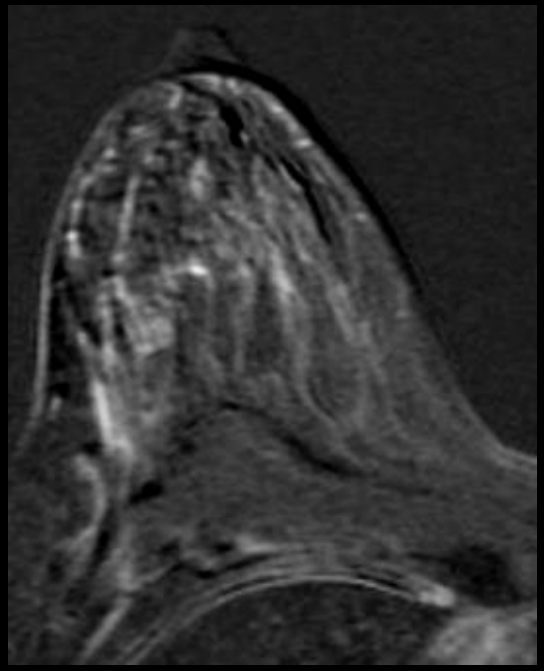

COMPARAISON
Bilans antérieurs

IRM Anormale

CONTEXTE CLINIQUE !!!
DDR
Sein traité
Annexectomie Prophyl

Mammographie, Echographie ciblées

Rehaussement IRM non Masse

Rehaussement IRM Masse

Rechercher Ca+ en Mammo

Rechercher anomalie surtout Echo et en Mammo

Femme mutée *BCRA1*, 54 ans,
ATCD de cancer de l'ovaire

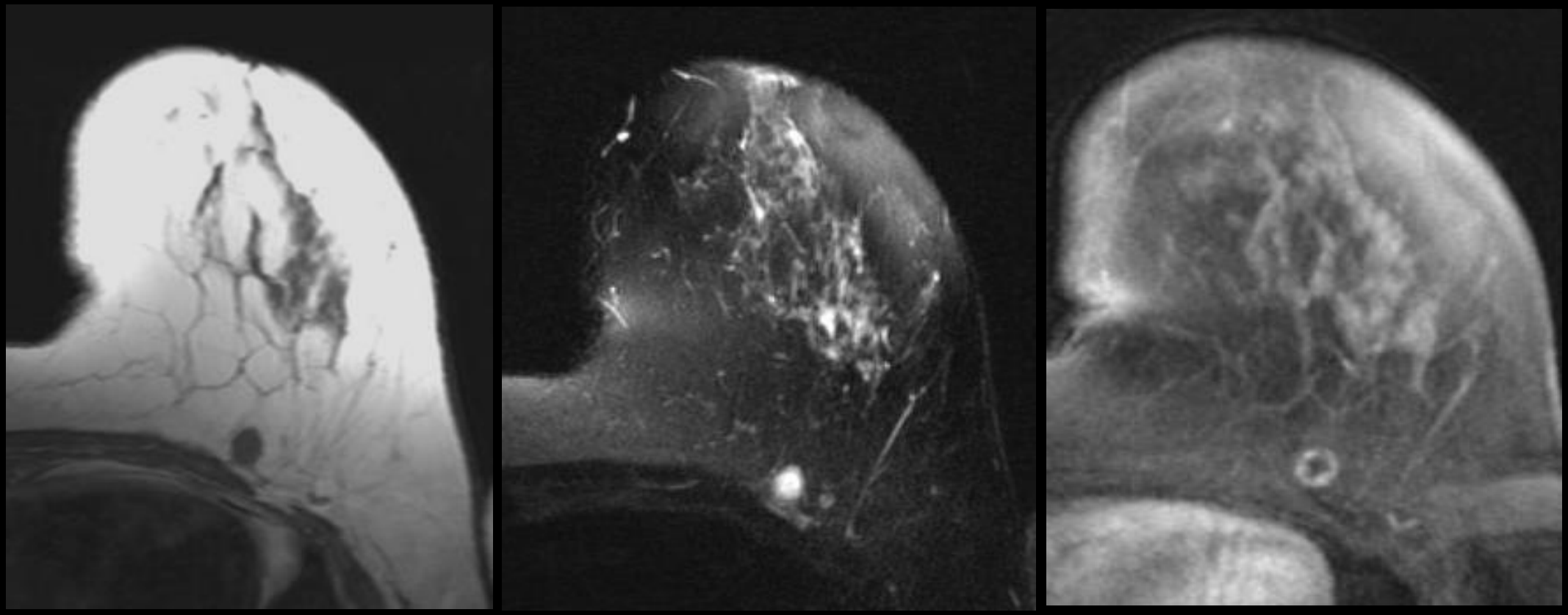

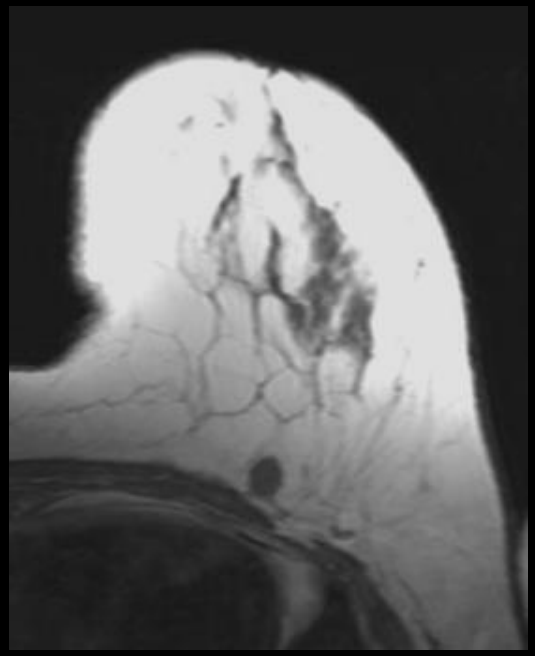

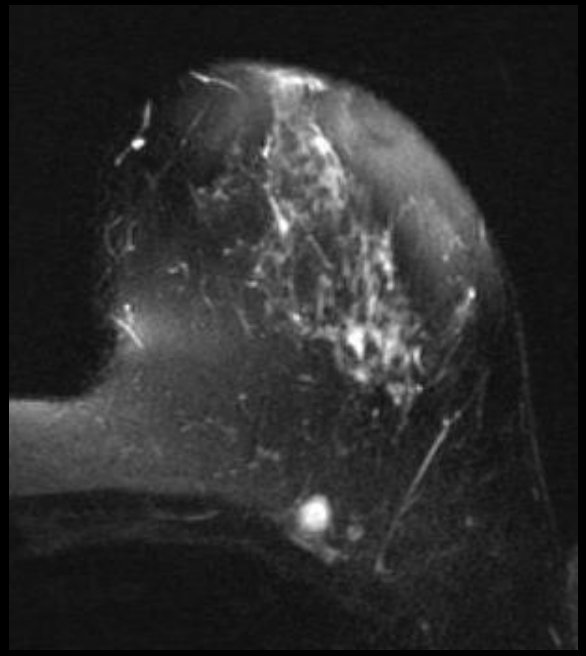

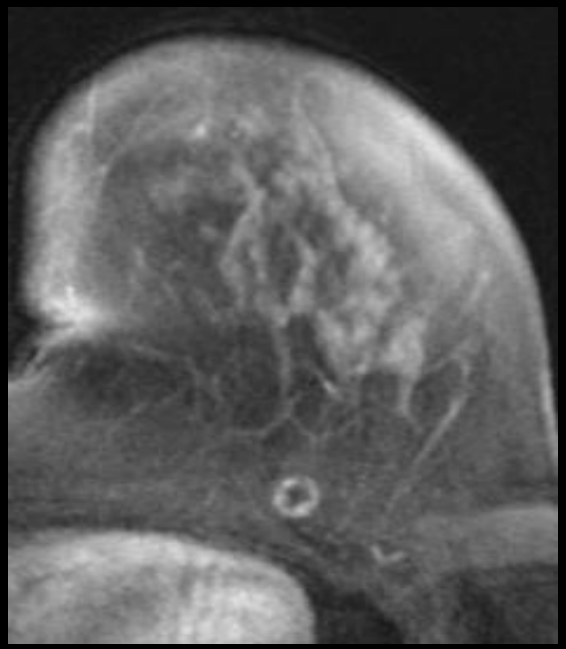

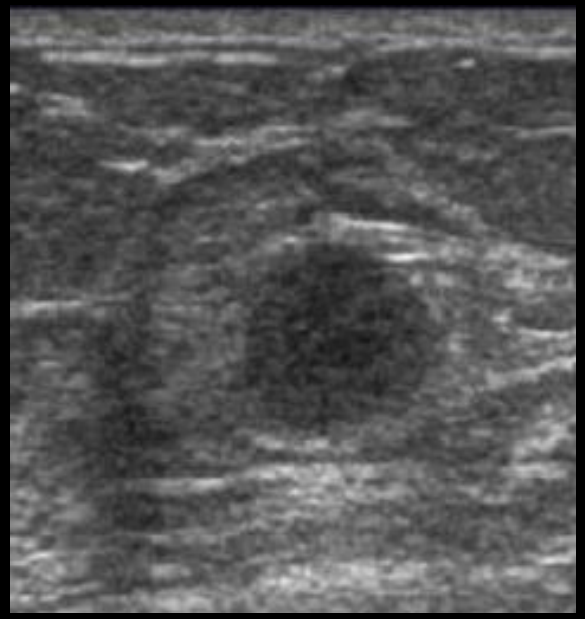

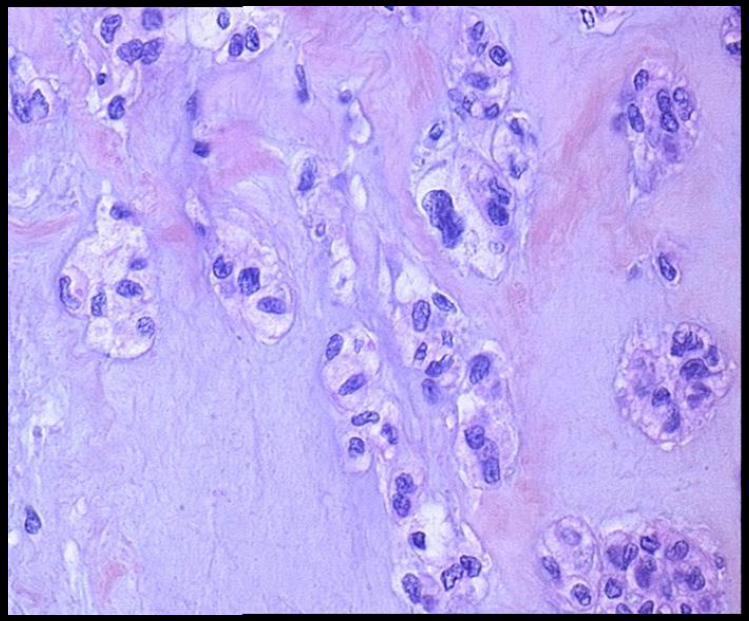

MBiopsies sous écho
CCI grade II
Carcinome métaplasique
à stroma
chondroïde

Particularités des Cancers *BRCA1*

- Le CCIS rare (en fait survient 12 ans + tôt/ pop Gen)
  - *BRCA* 1: CCIS de haut grade
- Canalaire Infiltrant, Triple -, de <u>type basal</u>

  Prolif élevée / RH-/Her2-/ <u>Ck 5 +/ p53+/EGFr +</u>
  - Mammo : Cancers ronds sans spicules
  - Echo: masse très hypoéchogène (pseudo-kystique)
  - IRM : Cinétique maligne (intensité, washout)
    - Siège préférentiel = pré- pectoral

- IRM: K infiltrants avec une présentation non masse

Femme mutée *BRCA2*, indemne. Bilan précédent normal

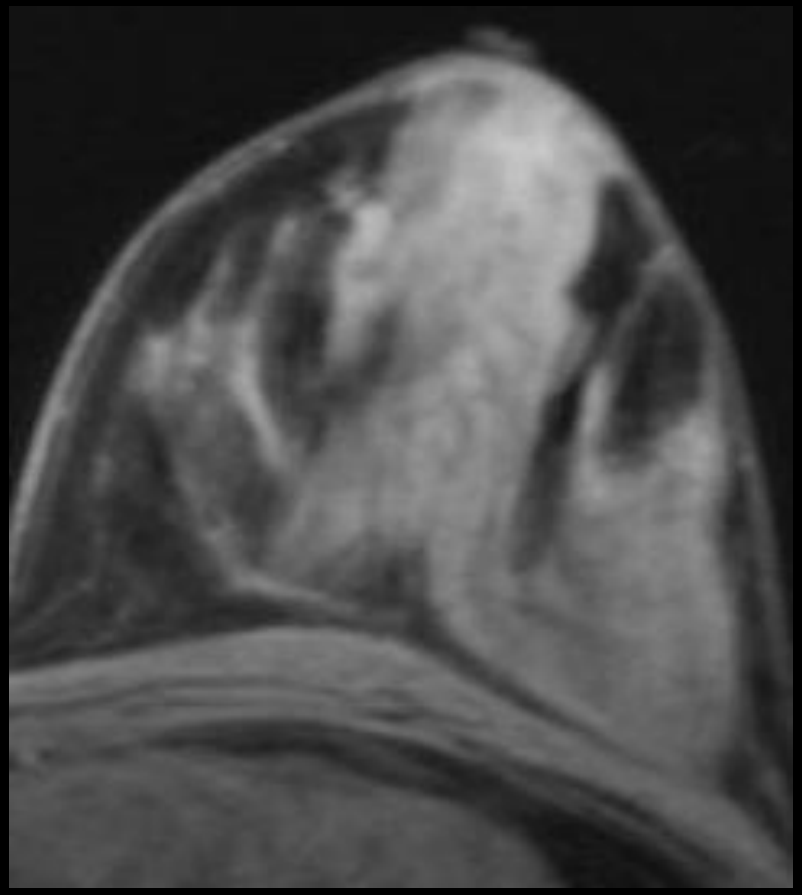

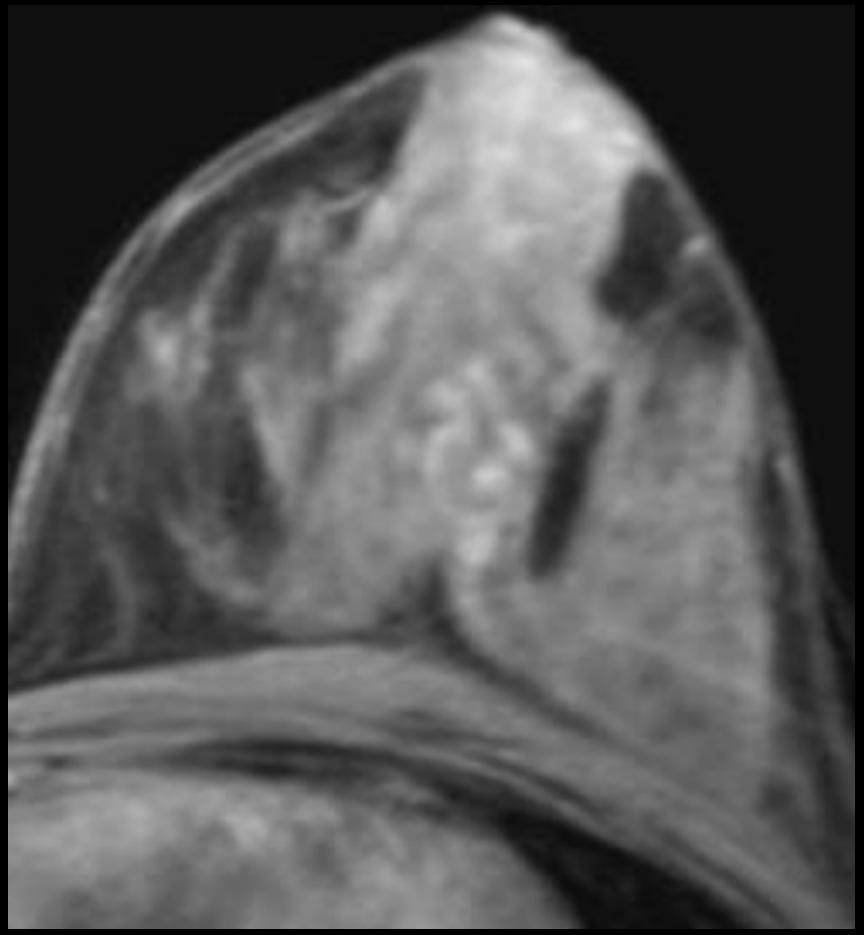

Femme mutée *BRCA2*, indemne. Bilan précédent normal

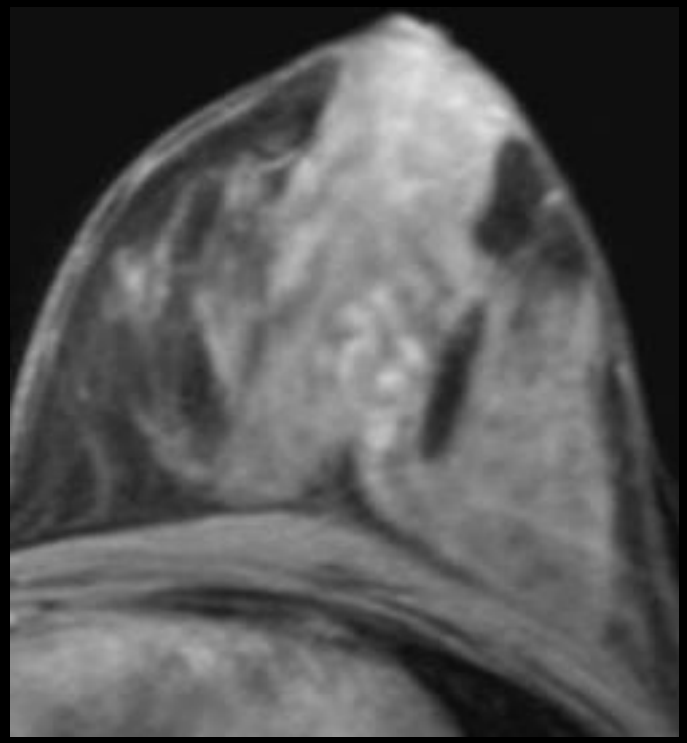

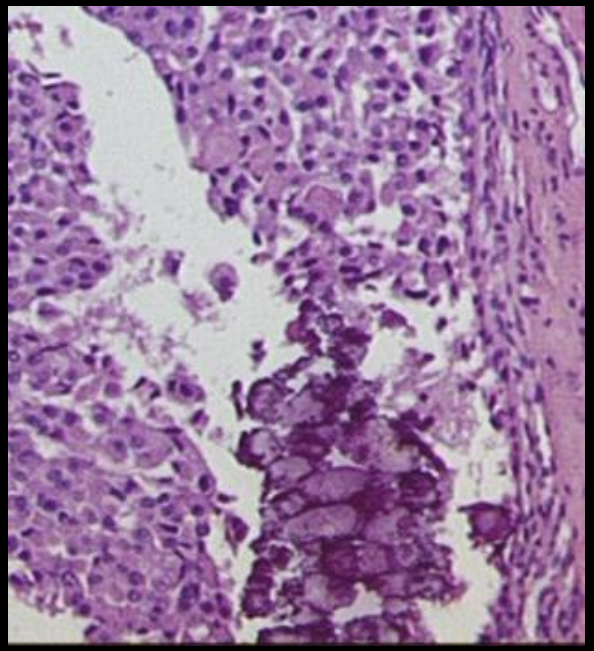

CCIS nécrose

Tout Va Bien

IRM + avec
Substratum en Mammo et/ou Echo

IRM ANORMALE

Eviter ACRO si lésion suspecte
DANGER

↓

ACRO en attente de l'échographie ciblée
DANGER

↓

Echographie ciblée normale
DANGER: on surveille un cancer ?

Femme mutée *BRCA2*, indemne

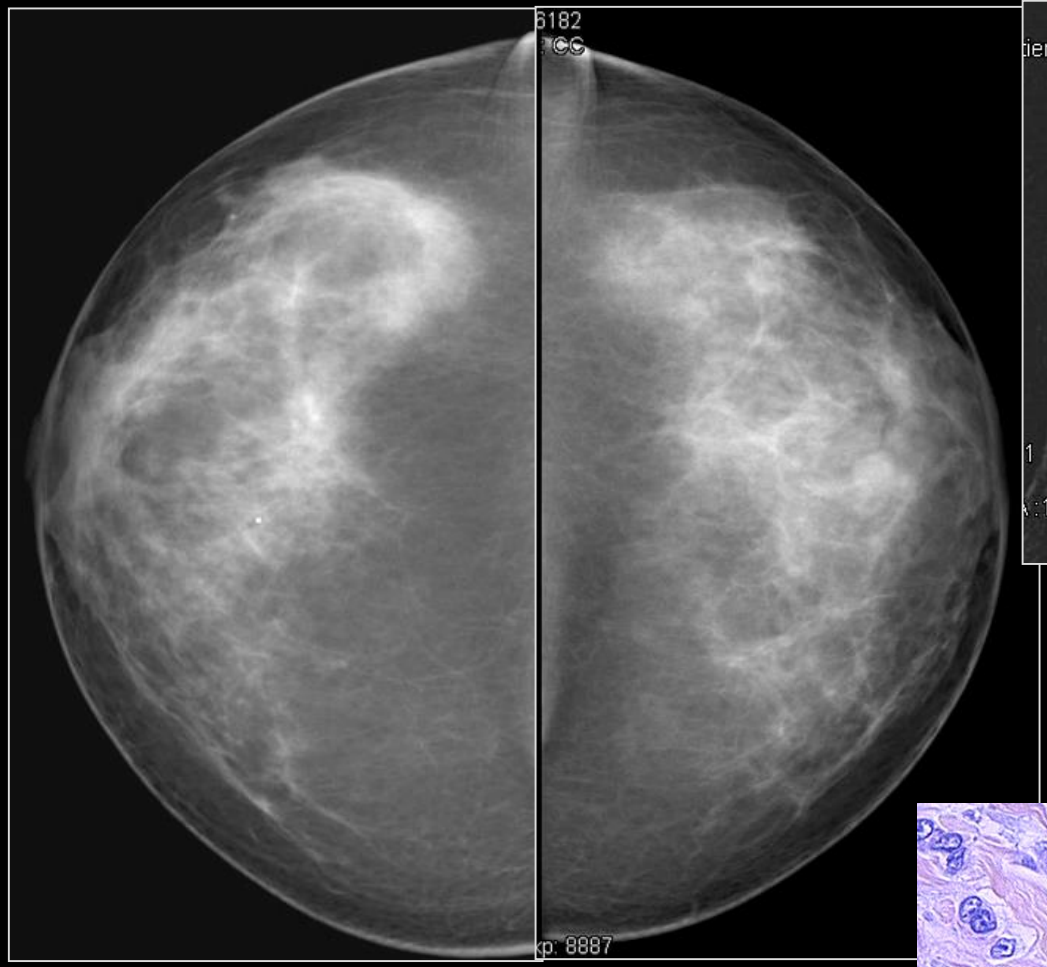

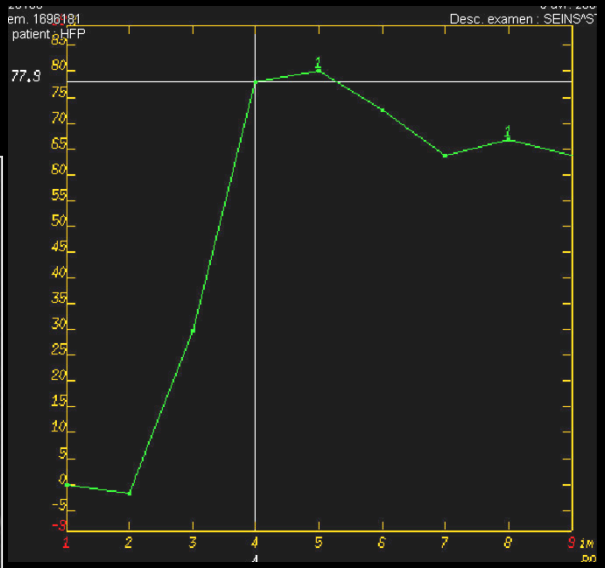

Echographie ciblée -

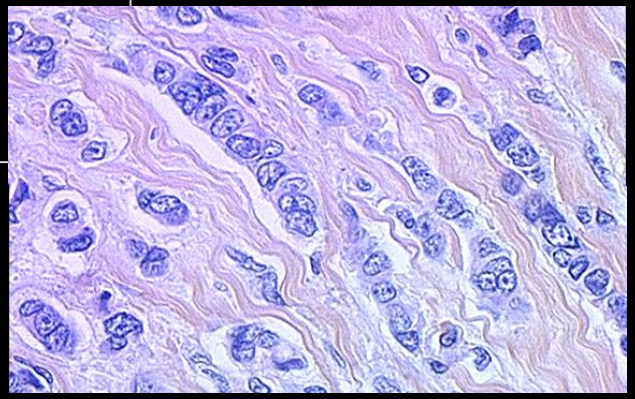

CCI grade 2

Signes IRM Suspects

Masse

Contour irrégulier, spiculé
Rehaussement HeteroG
Courbe plateau/washout
Topographie (zones interdites)
Evolutivité

Non Masse

Asymétrique
Distribution canalaire/segmentaire
Rehaussement micronodulaire
Distribution régionale, hétérogène
Evolutivité

Mutée *BCRA1*, ATCD sein Dt, Annexectomie Prophyl.

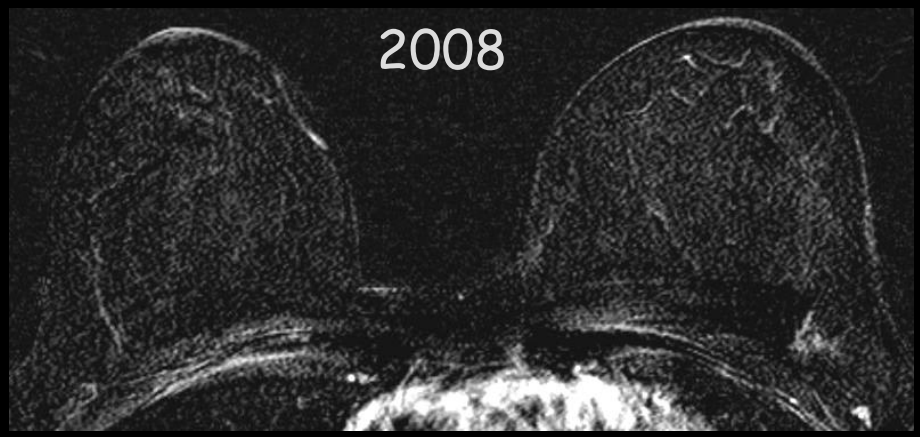

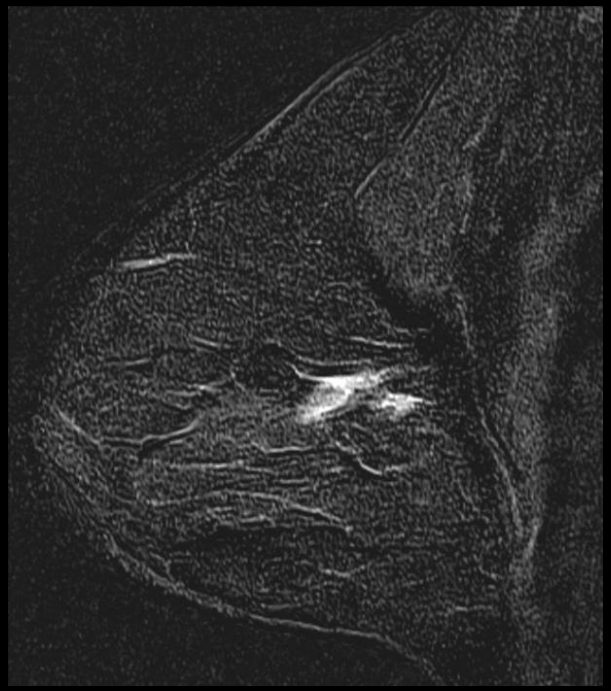

Suspect ?
CAT ?

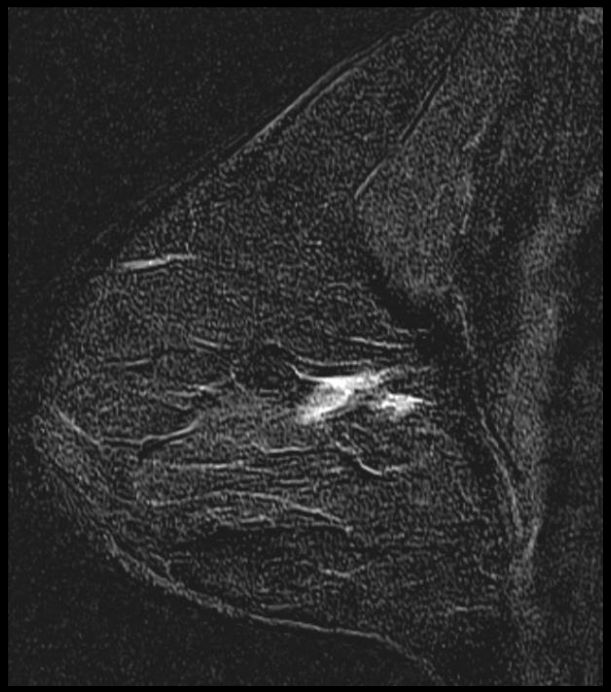

Suspect
Mammographie, Echo normales

↓

Macrobiopsies guidées sous IRM

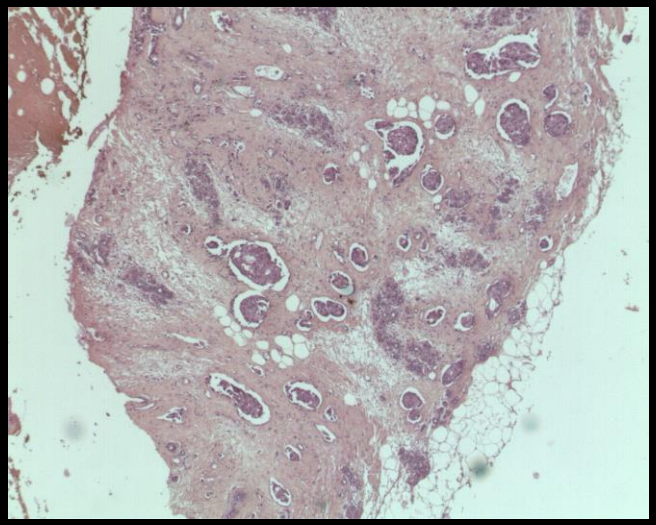

Adénocarcinome infiltrant
probablement de type mixte lobulaire et canalaire apocrine.
Association à une lymphangite carcinomateuse.
Grade histopronostique (EE) : II.
Triple négatif

Femme mutée *BRCA1*, indemne

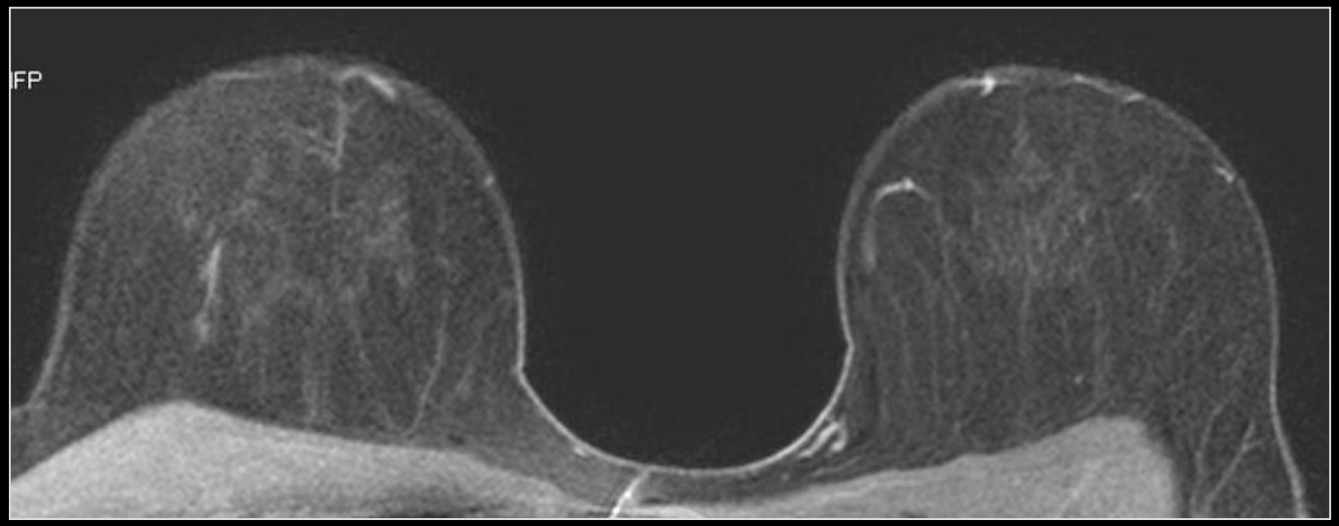

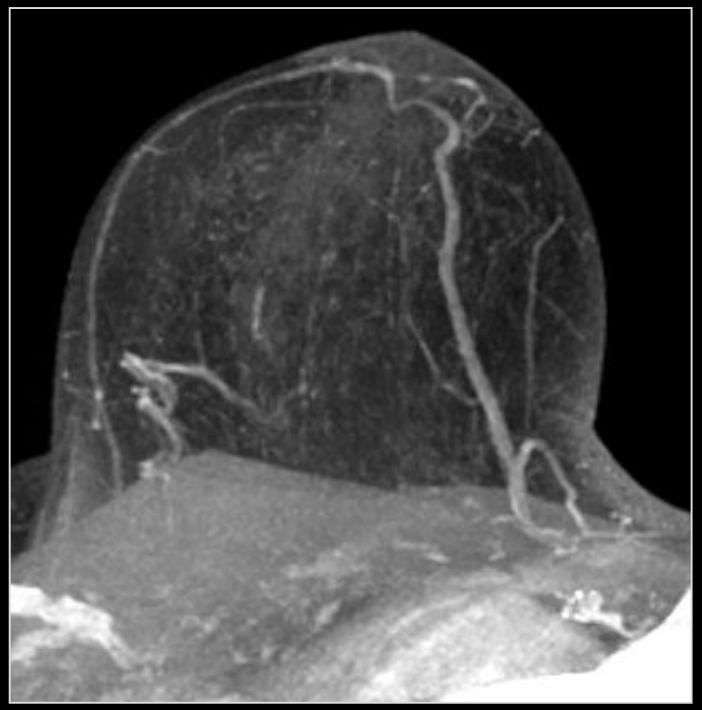

Suspect ?
CAT ?

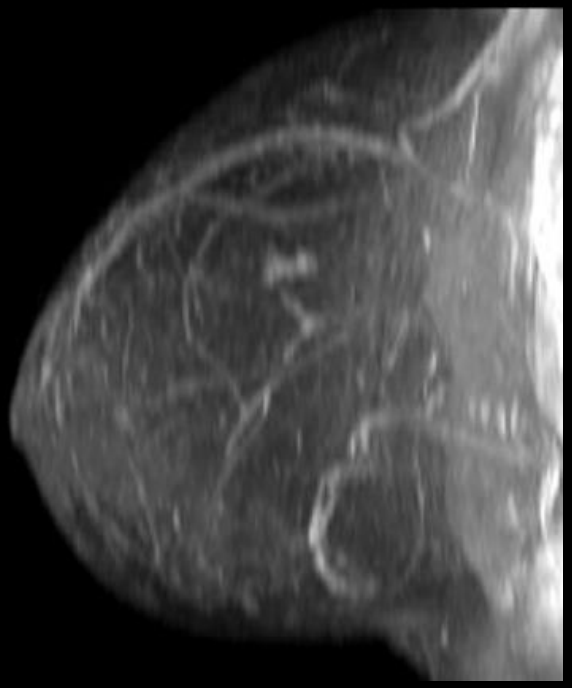

Suspect
Mammographie normale

↓

Macrobiopsies guidées sous IRM

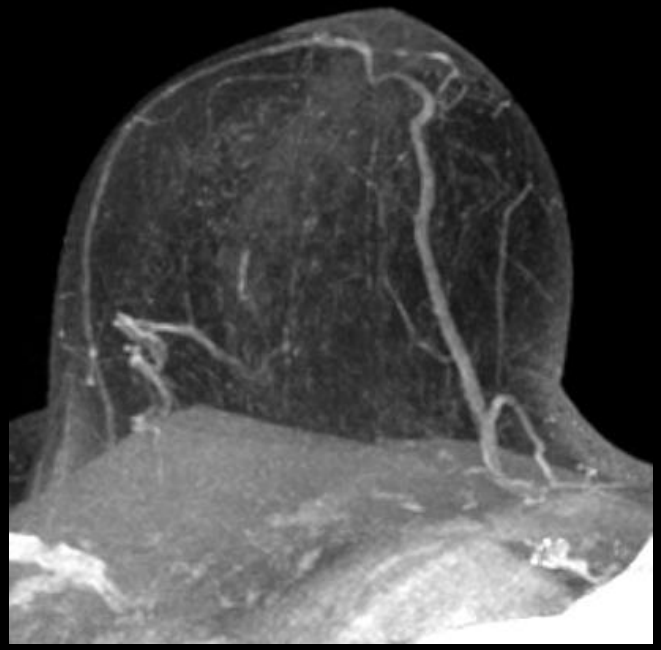

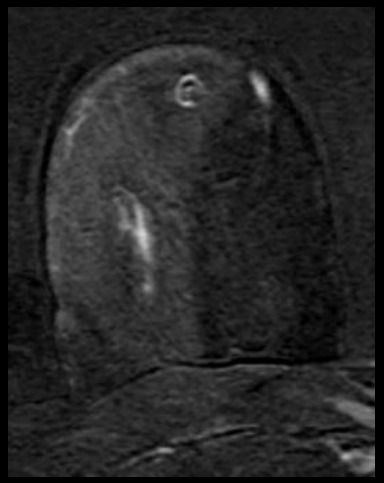

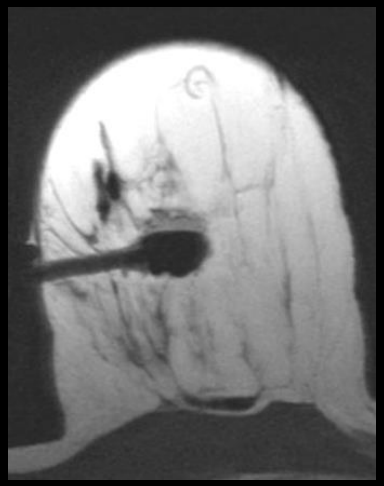

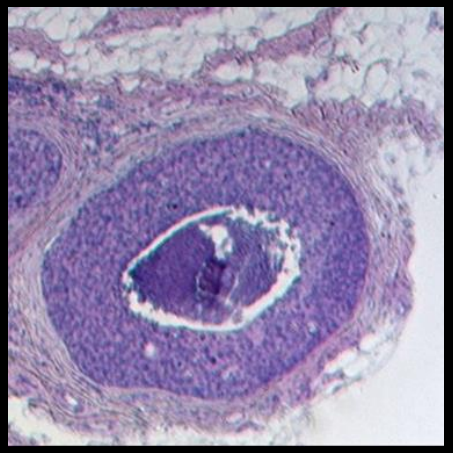

FOYER Isolé → Eliminer gglion

↓

Echographie Ciblée

Normale

Positive → Prélèvements

Classé ACR 3 si:

- Femme préménop/Indemne
- Topographie Glandulaire
- Taille stable ds le temps
- % rehaussement > 100%
- Absence de washout

Classé ACR 4 si:

- Femme ménop/Sein traité
- Topographie zone interdite
- Evolutif (comparaison)
- Δ Taille au cours du temps
  - « Blooming sign »
- Washout +

Femme mutée *BCRA1*, 39 ans, indemne

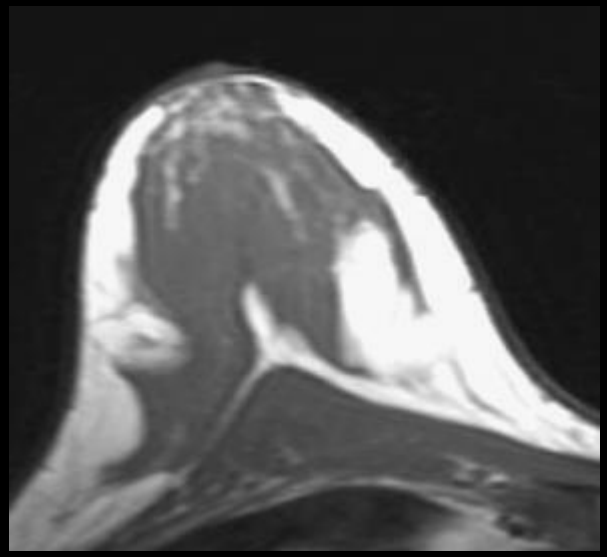

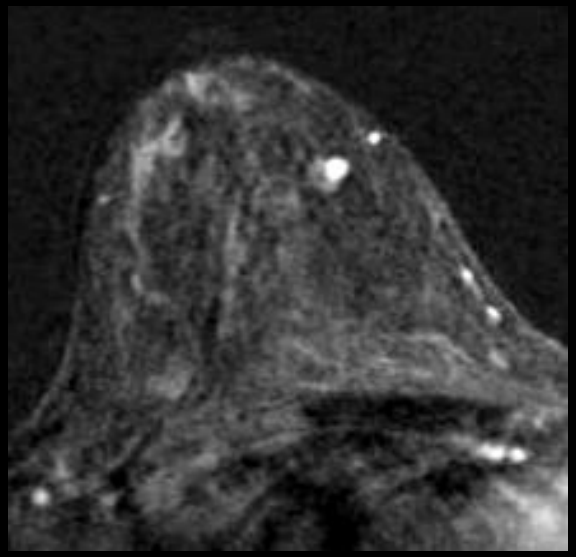

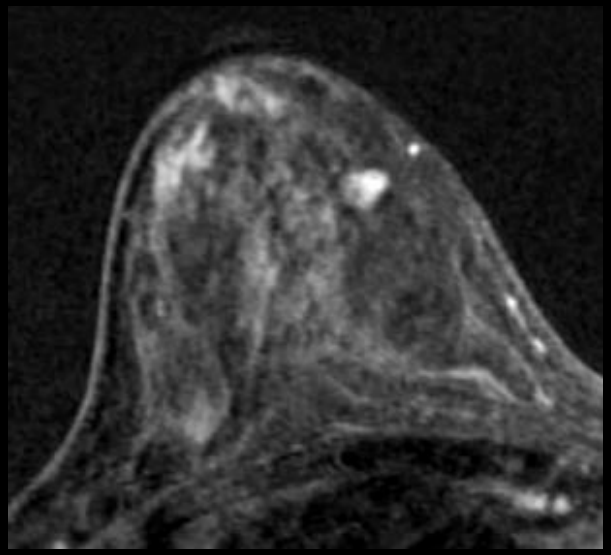

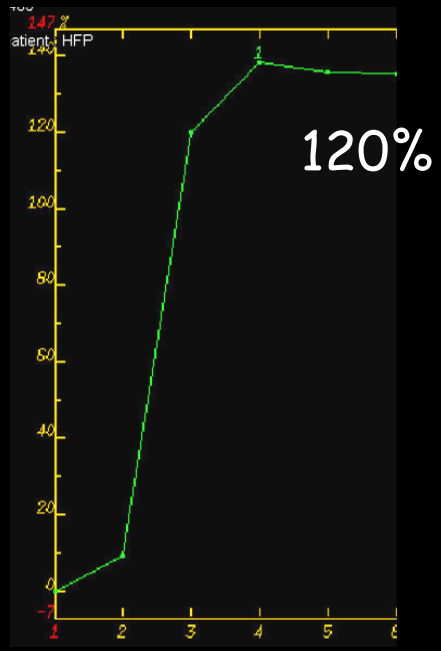

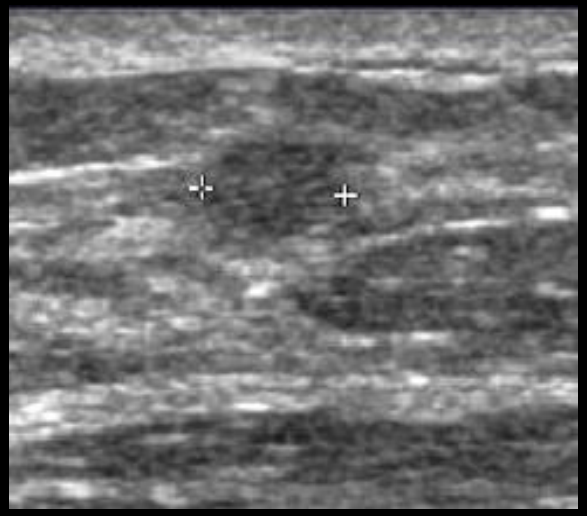

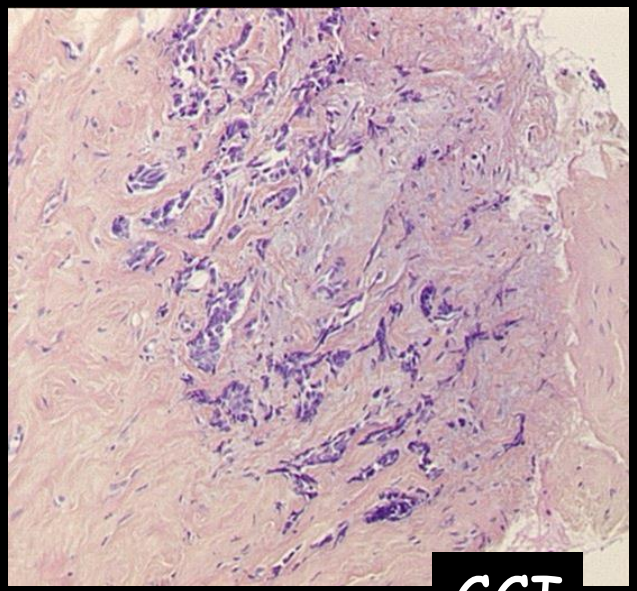

Mutation *BRCA1*, ATCD de tt conservateur bilatéral

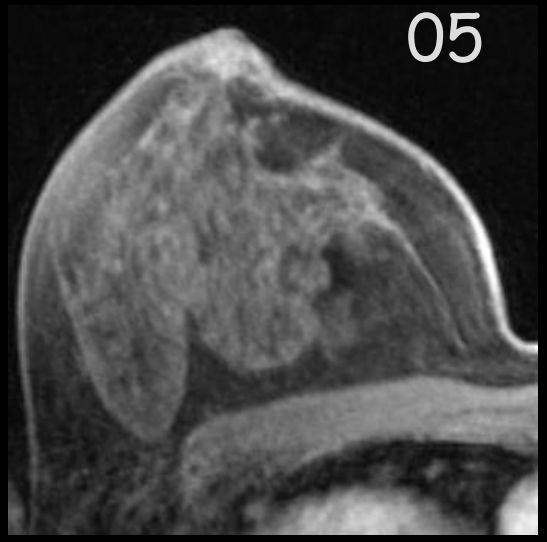

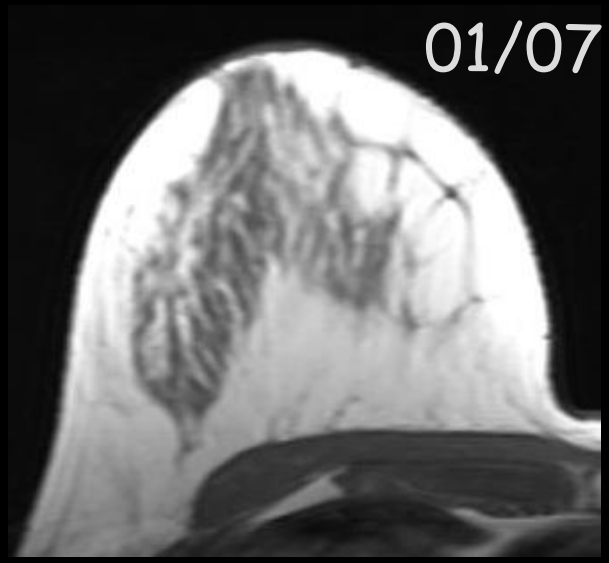

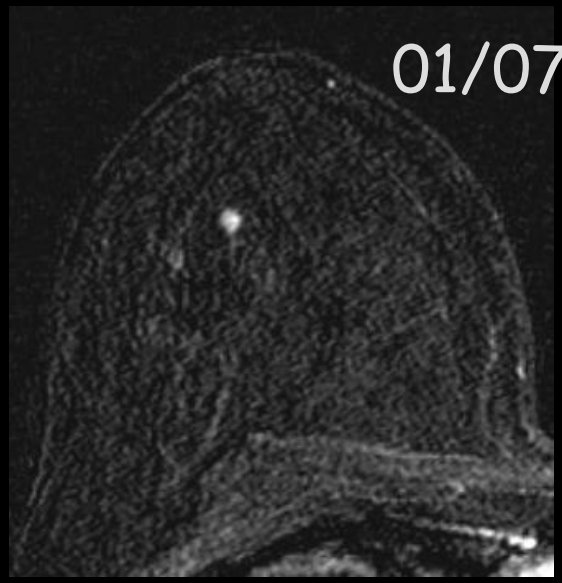

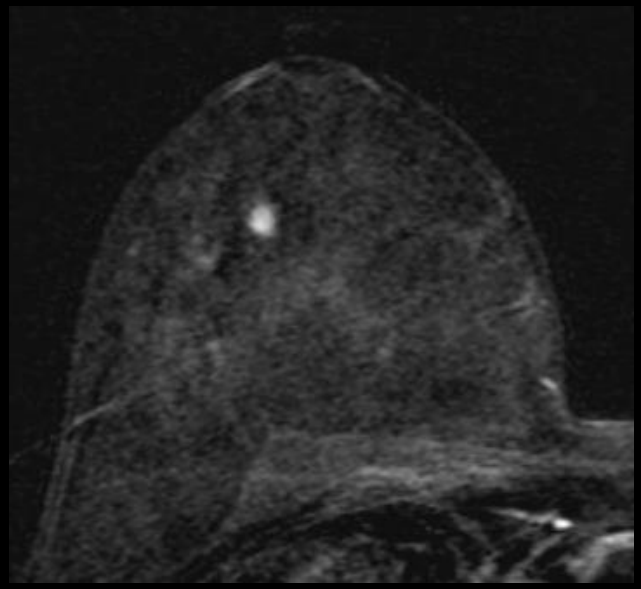

07/07

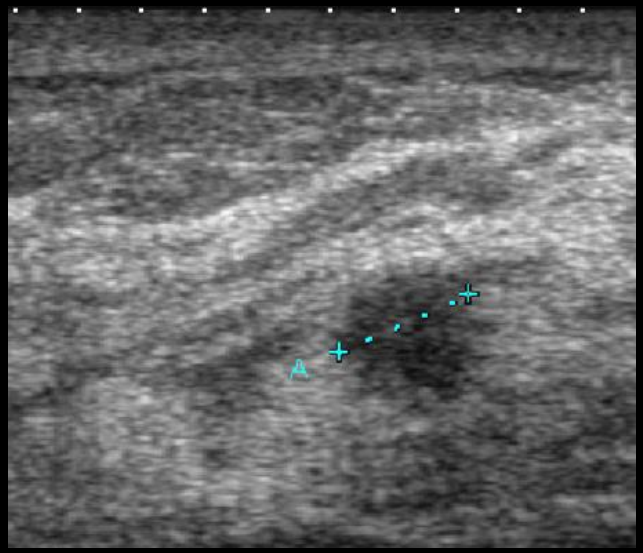

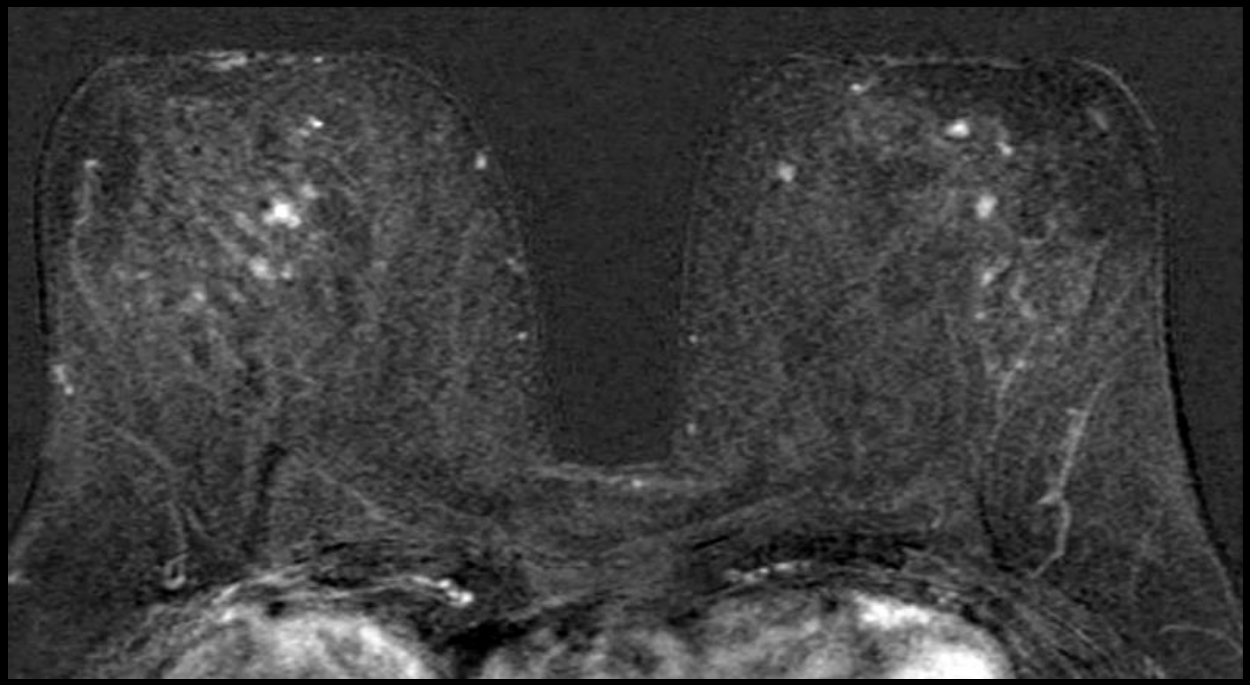

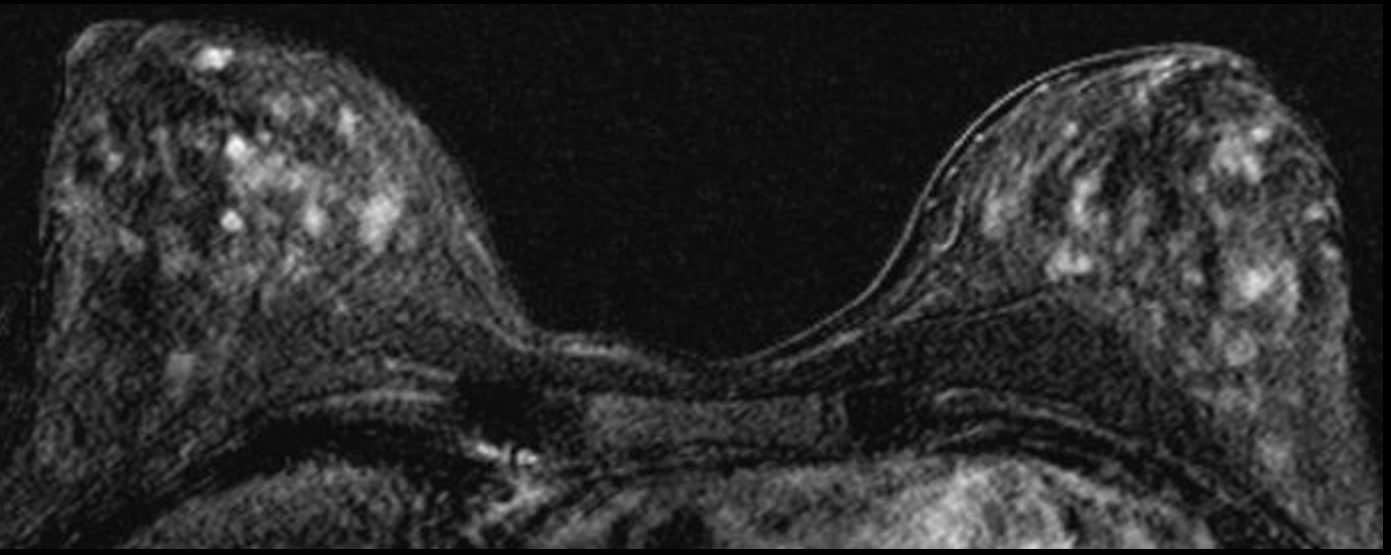

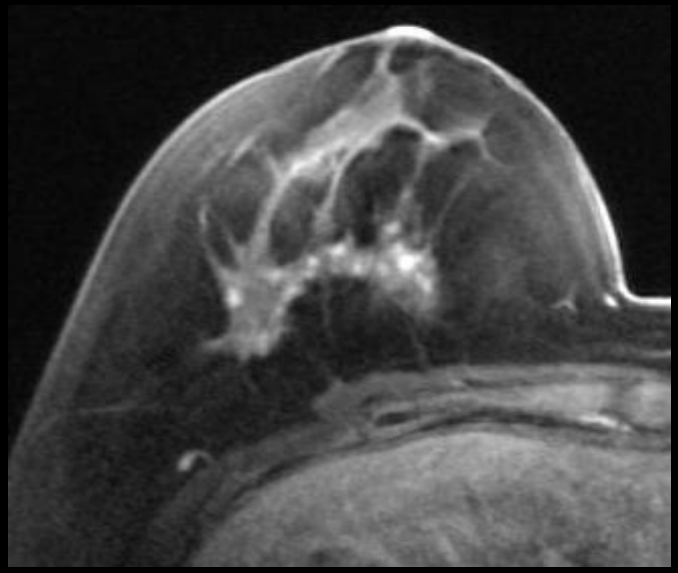

Il n'y a pas que l'IRM….

Femme de 72 ans
ATCD K Sein G (CLI)
3 ATCD K seins au 1er degré
Mammo et écho ciblée -

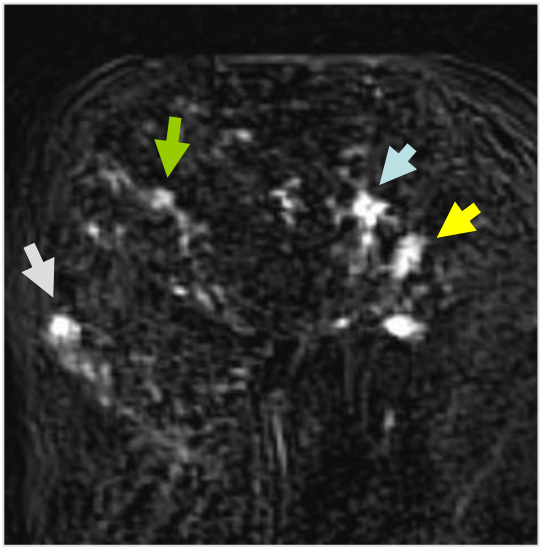

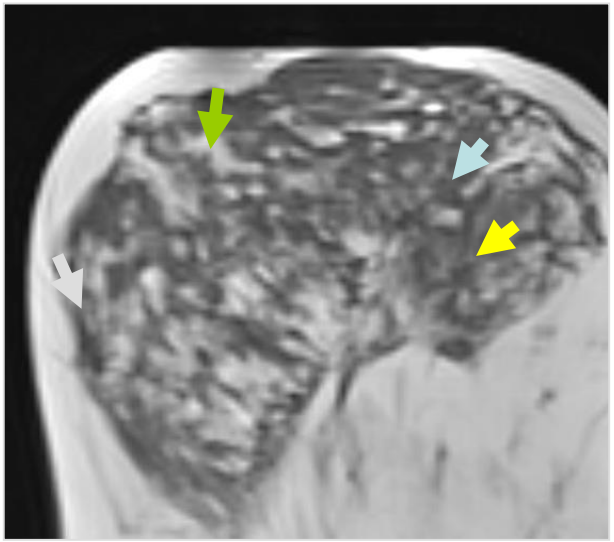

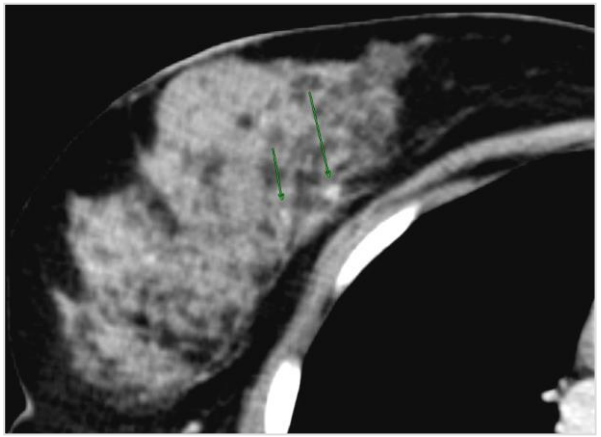

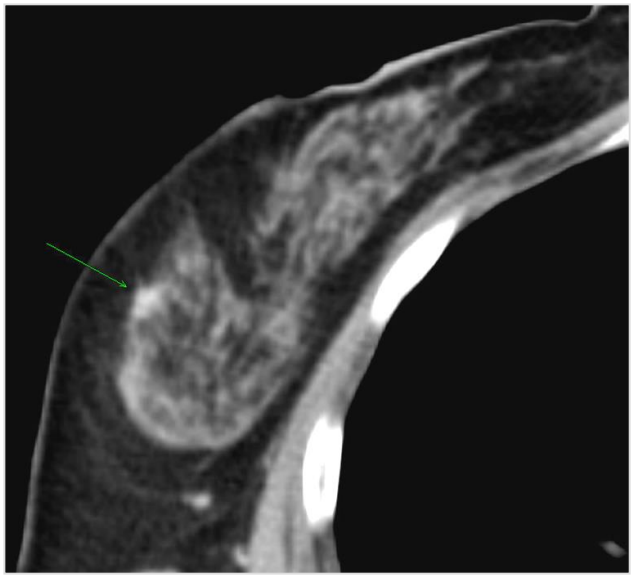

Il n'y a pas que l'IRM….

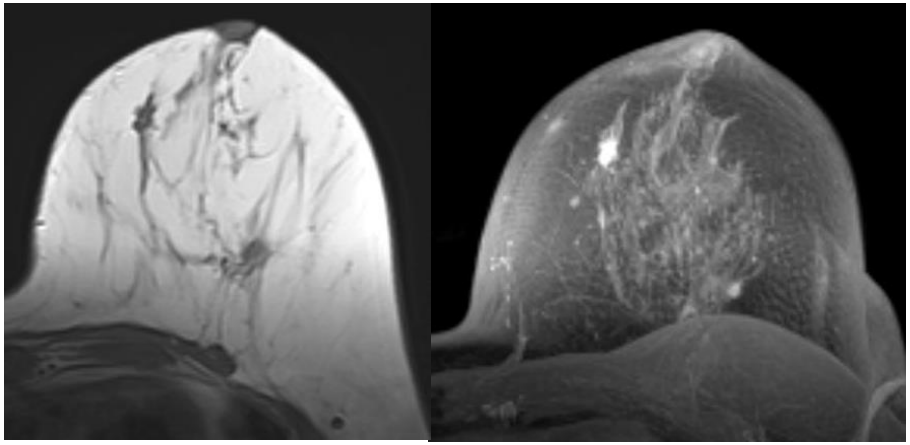

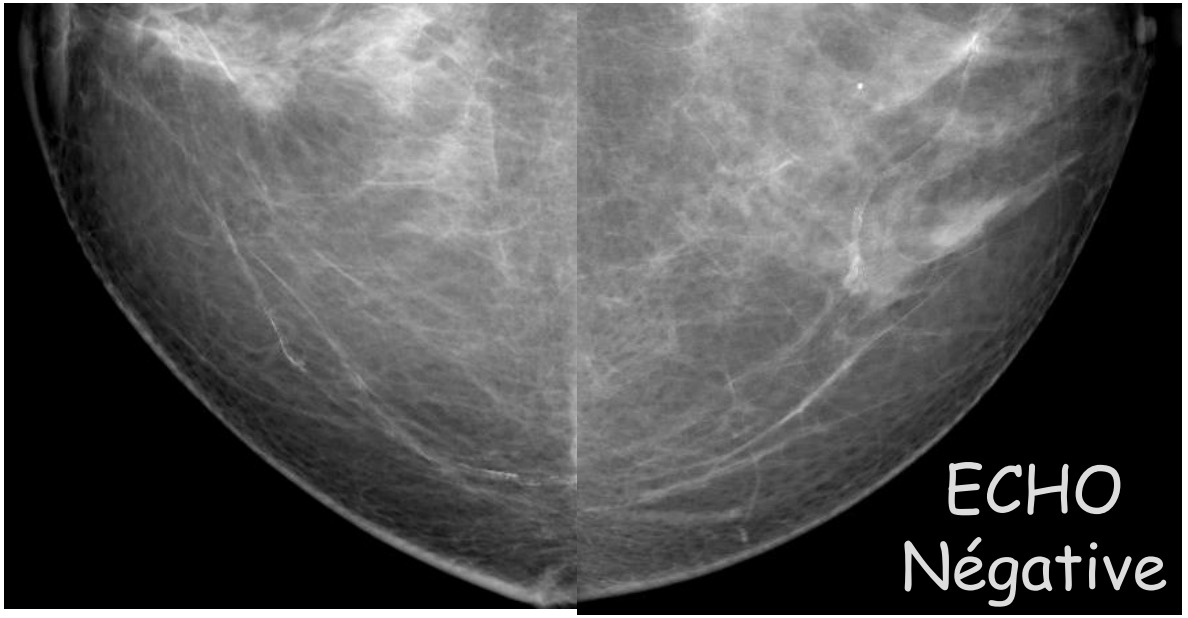

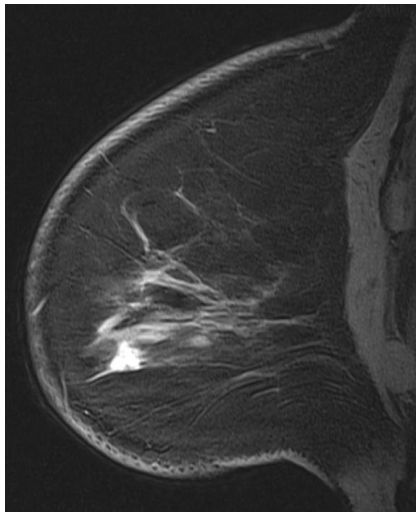

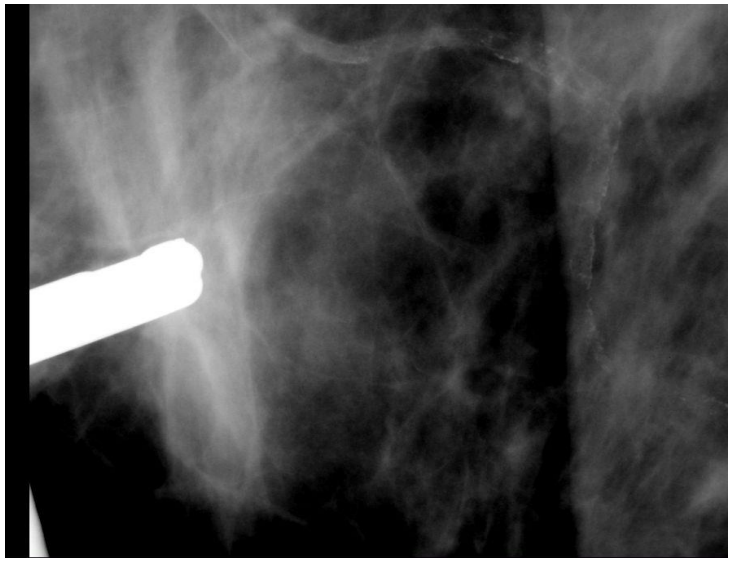

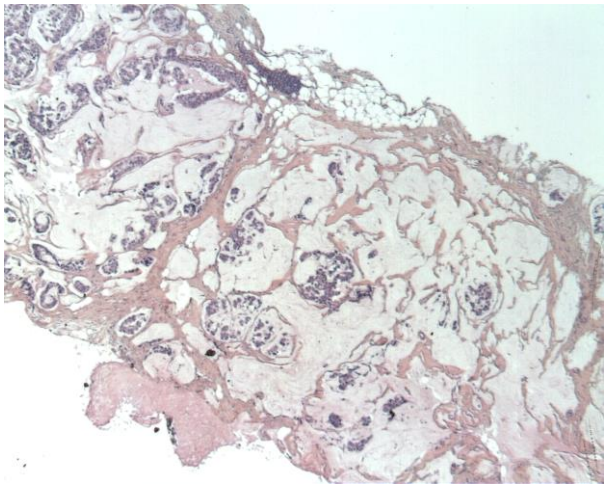

Ce que l'on ne sait pas

- Quand arrêter l'IRM ?
  - Médico –économique UK: 49 ans, Pays Bas: 55 ans
- Quand commencer la mammographie ?
  - EUSOMA => 35 ans
- Utilité de la Mammographie ?
  - Une seule étude (EVA) : pas de valeur ajoutée à l'IRM
- Examens alternés tous les 6 mois ?

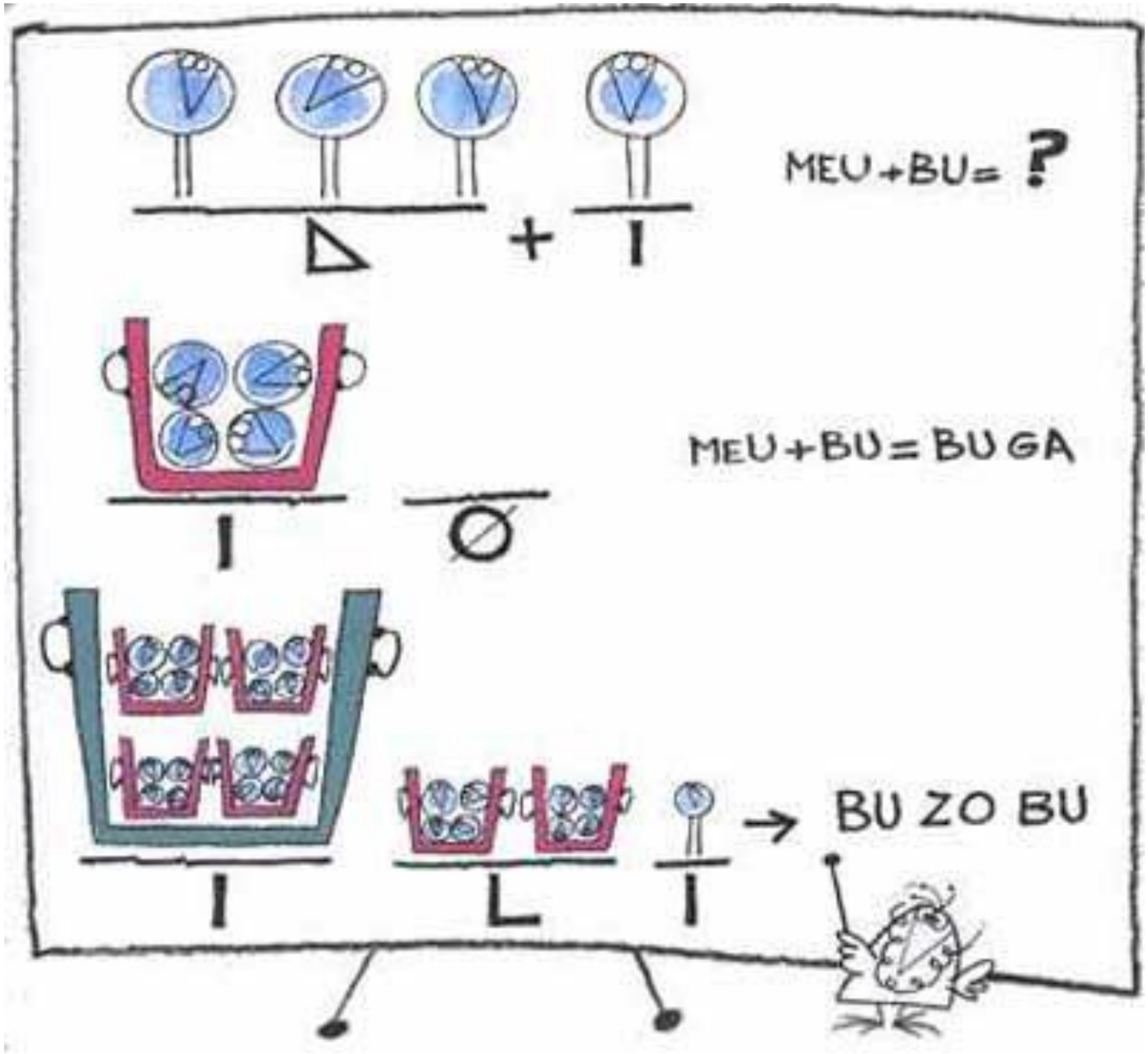
MEU+BU= ?
MEU+BU=BUGA
BU ZO BU