Place de la TEP au Fluoroestradiol et au Trastuzumab dans la prise en charge du cancer du sein métastatique

Pr Alexandre Cochet

Centre Georges-François Leclerc, Dijon, France.
LE2i CNRS UMR 6306, Dijon, France.

Cancer du sein métastatique

- Métastatiques *de novo*: <10%
- Métastatiques secondairement: 30%
- Médiane de survie: 36 mois
- Thérapies ciblées: hormonothérapies (RH+), anti-HER2
- Nouvelles alternatives thérapeutiques: anti CDK 4/6, anti mTOR…

Nécessité de développer des biomarqueurs pour prédire ou apprécier précocement la réponse au traitement

Hétérogénéité du cancer du sein

Maladie hétérogène en tenant compte des altérations moléculaires, du phénotype cellulaire et de l'évolution clinique

Basal-Like Breast Cancer	*TNBC*	HER2+	Luminal A	Luminal B
(10%)	(15-20%)	(11%)	(73%)	
• Expression of markers expressed in normal basal/myoepithelial cells • **Associated with** ER-, PR-, HER2- , CK5/6 +, EGFR+ • BUT can infrequently express ER, PR and HER2 • A majority of BLBC are mutated BRCA1	• *ER-, PR- and HER2-* • Generally ER- means ERα- BUT can be ERβ + • CXCL8+ • PARP-1+++ • **Associated** with BRCA1 and BRCA2 deficiency - 11%	• HER2+++, ER-, PR-	• ER+, PR+ HER2- • Low Ki67	• ER+, PR+ HER2+ • FoxA1++++ Ki67+, CCNB1+, MYBL2 +

Overlap

Overlap

Classification en constante évolution

 # 70% des cancers RH+
 # 20% des cancers HER2+

Hétérogénéité de la maladie métastatique

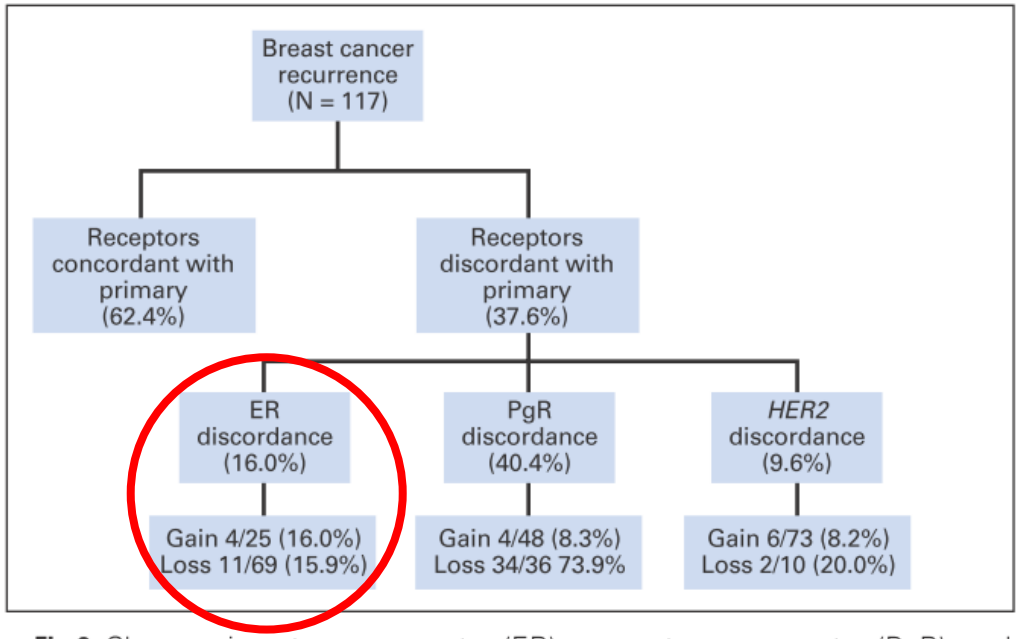

Fig 2. Changes in estrogen receptor (ER), progesterone receptor (PgR), and *HER2* between the original pathology report of the primary tumor and the metastasis.

Amir E, *J Clin Oncol* 2011;30:587-592

Nécessité de rebiopsier?

ESMO 2012 Estrogen, progesterone and HER-2 receptors of the metastatic lesion should be obtained at least once in the evolution of the disease, if technically possible, and particularly if not available from the primary tumor

TEP au ^{18}F-Fluorodésoxyglucose (FDG)

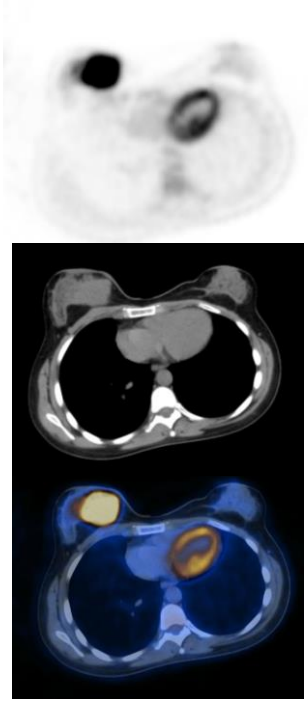

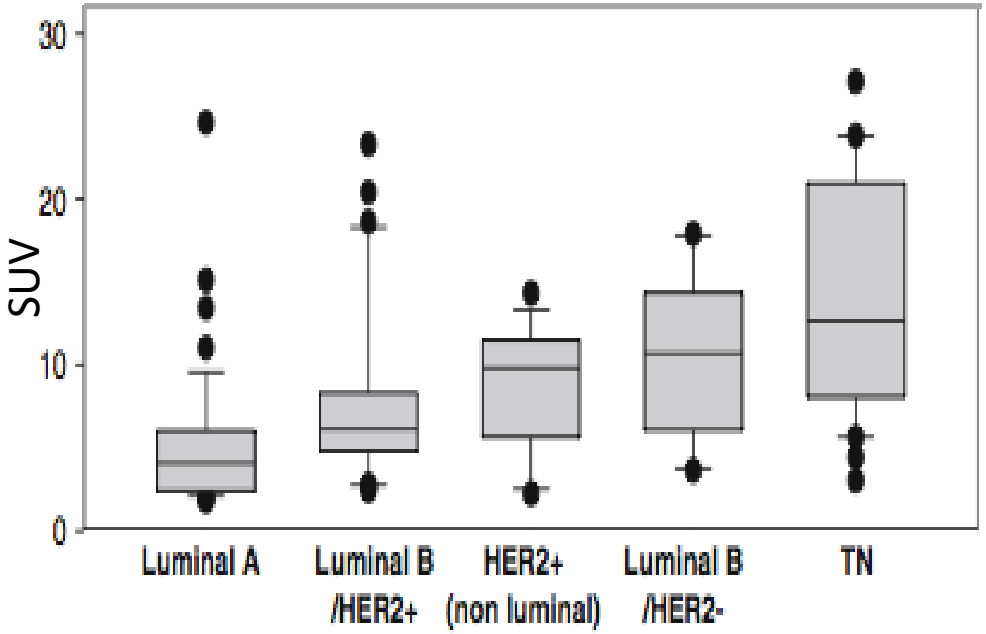

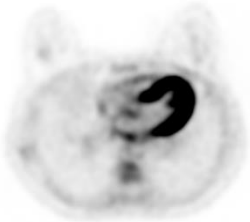

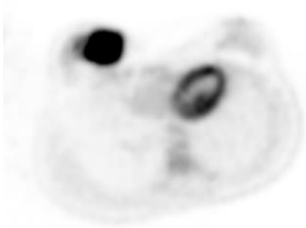

$$SUV = \frac{\text{A(tumeur) x Poids}}{\text{A (injectée)}}$$

Cochet A, *Eur J Nucl Med Mol Imaging* 2014;41:428-37

TEP au 16α-[^{18}F]-17β-oestradiol (FES)

17β-oestradiol

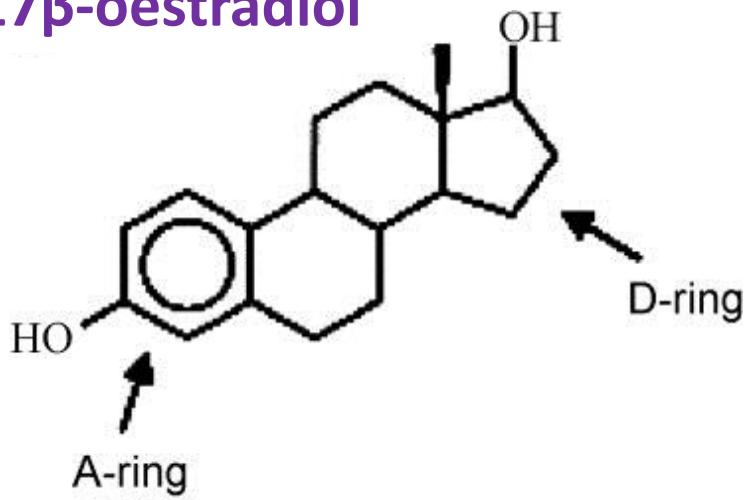

16α-[^{18}F]-17β-oestradiol (FES)

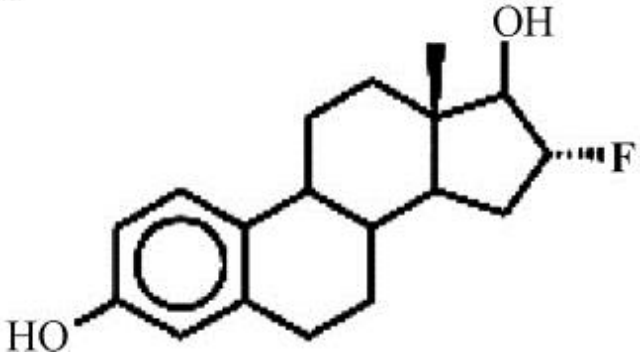

Elimination biliaire, cycle entéro-hépatique, élimination urinaire

Affinité pour ERα >> ERβ

Corrélation entre fixation FES et expression ER

FIGURE 5. Comparison of ^{18}F-FES uptake measures with IHC index (Photoshop analysis). Treated patients are identified by closed circles.

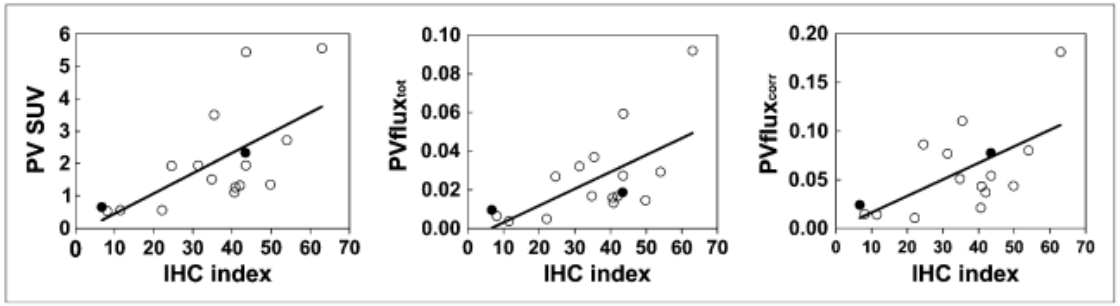

Peterson LM, *J Nucl Med* 2008;49:367-374

Facteurs influençant la fixation de FES

↗ SHBG: ↘ FES
↗ BMI: ↗ FES
Pas d'influence de l'âge/taux d'oestradiol

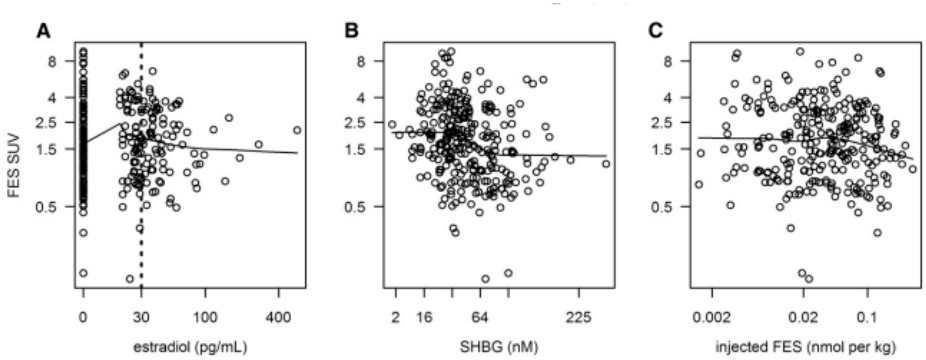

Peterson LM, *Nucl Med Biol* 2011;38:969-978

Anti-oestrogènes: ↘ ↘ FES
Inhibiteurs aromatase: ↘ FES (-14%)

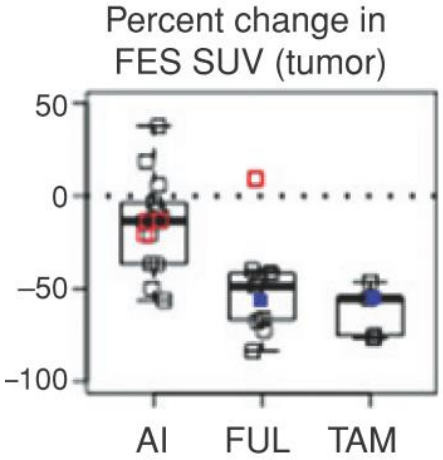

Linden HM, *Clin Cancer Res* 2011;17:4799-805

Un traceur très spécifique

	Biopsy results	Sensitivity or specificity (95% CI)	Number of lesions
Sensitivity			
Dehdashti et al[61]	ER-positive tumour	69% (44–86)	16
Mintun et al[3]	ER-positive tumour	100% (77–100)	13
Mortimer et al[60]	ER-positive tumour	76% (55–89)	21
Peterson et al[47]	ER-positive tumour	100% (76–100)	12
Overall	..	84% (73–91)	62
Specificity			
Dehdashti et al[61]	Benign	100% (68–100)	10
Dehdashti et al[61]	ER-negative tumour	100% (82–100)	17
Mortimer et al[60]	ER-negative tumour	100% (84–100)	20
Peterson et al[47]	ER-negative tumour	80% (38–96)	5
Overall	..	98% (90–100)	52

ER=oestrogen receptor.

Table 2: Sensitivity and specificity of 16α[^{18}F]-fluoro-17β-oestradiol PET

van Kruchten M, *Lancet Oncol* 2013;14:e465-475

Hétérogénéité de la maladie métastatique

FDG **FES**

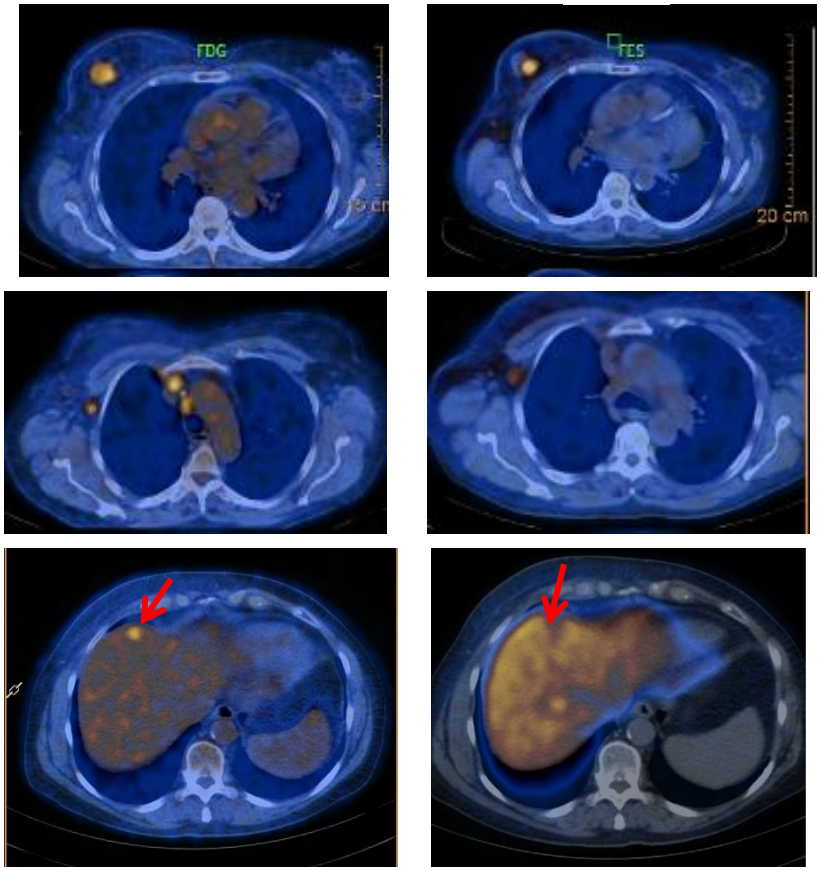

Can Fluorine-18 Fluoroestradiol Positron Emission Tomography—Computed Tomography Demonstrate the Heterogeneity of Breast Cancer In Vivo?

Zhongyi Yang, Yifei Sun, Yongping Zhang, Jing Xue, Mingwei Wang, Wei Shi, Beiling Zhu, Silong Hu, Zhifeng Yao, Herong Pan, Yingjian Zhang

Clinical Breast Cancer, Vol. 13, No. 5, 359-63

37% des patients avec tumeur primitive ER+ présentent une ou des lésions secondaires FES-

15-47% des patients présentent à la fois des lésions FES + et FES -

Pas d'hétérogénéité constatée chez les patients métastatiques *de novo*

Quelles applications cliniques ?

PET Imaging of Estrogen Receptors as a Diagnostic Tool for Breast Cancer Patients Presenting with a Clinical Dilemma

Michel van Kruchten[1], Andor W.J.M. Glaudemans[2], Erik F.J. de Vries[2], Regina G.H. Beets-Tan[3], Carolien P. Schröder[1], Rudi A. Dierckx[2], Elisabeth G.E. de Vries[1], and Geke A.P. Hospers[1]

J Nucl Med 2012; 53:182–190
DOI: 10.2967/jnumed.111.092734

→ **Caractérisation de lésions litigieuses**

→ **Evaluation de l'expression de ER après échec d'une 1ère ligne d'hormonothérapie**

→ **Evaluation de l'origine de lésions métastatiques**

Impact thérapeutique de la TEP au FES: 48%

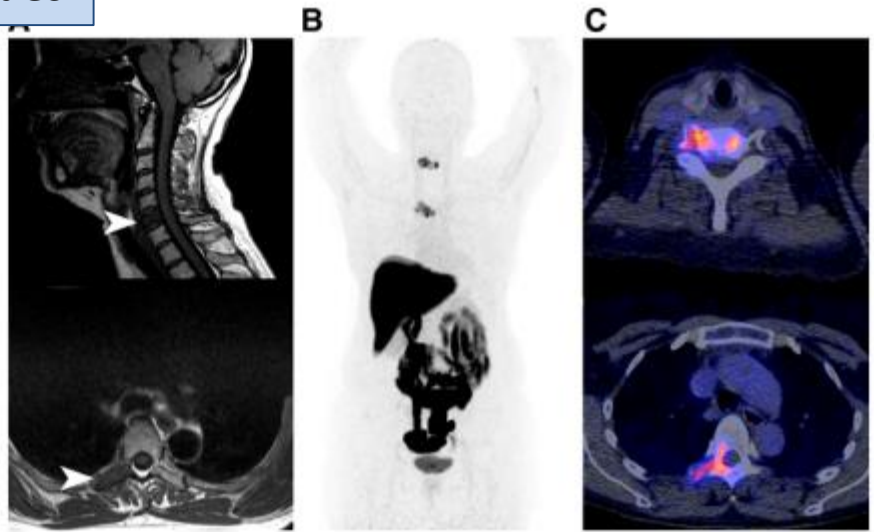

FIGURE 4. This patient presented with neurologic symptoms of root C6 5 y after primary breast cancer diagnosis. On MRI (A), pathologic processes were suspected in C6 and T4. Biopsy to prove that these were metastases and originated from prior primary breast cancer was considered too risky. ^{18}F-FES uptake was observed in suspected metastases in C6 and T4 (B). ^{18}F-FES PET/CT images (C) matched MRI findings. No other pathologic uptake was observed.

Prédiction de la réponse à l'hormonothérapie

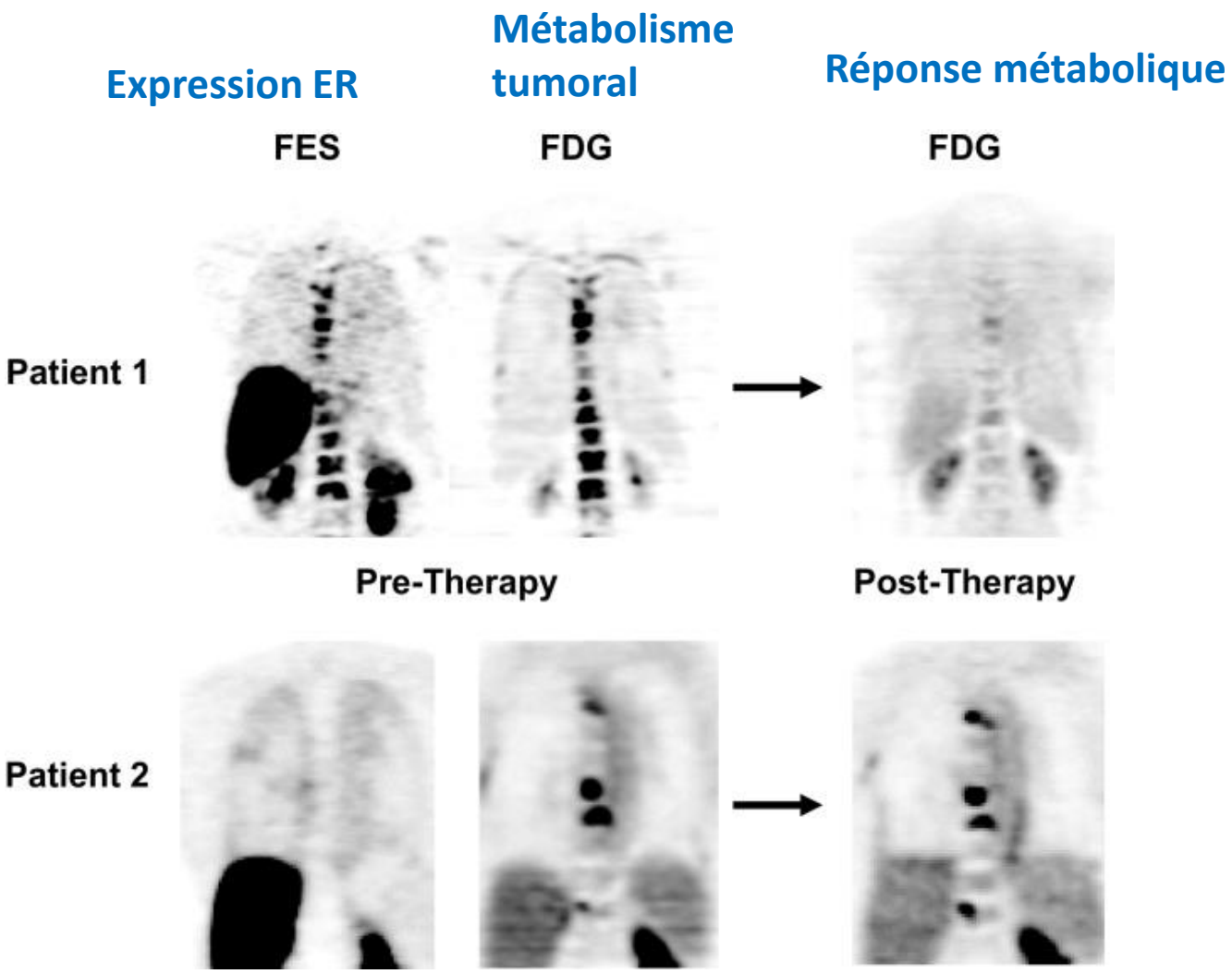

Linden *HM*, J Clin Oncol 2006;24:2793-2799

Prédiction de la réponse à l'hormonothérapie

VPP =65%

VPN= 88%

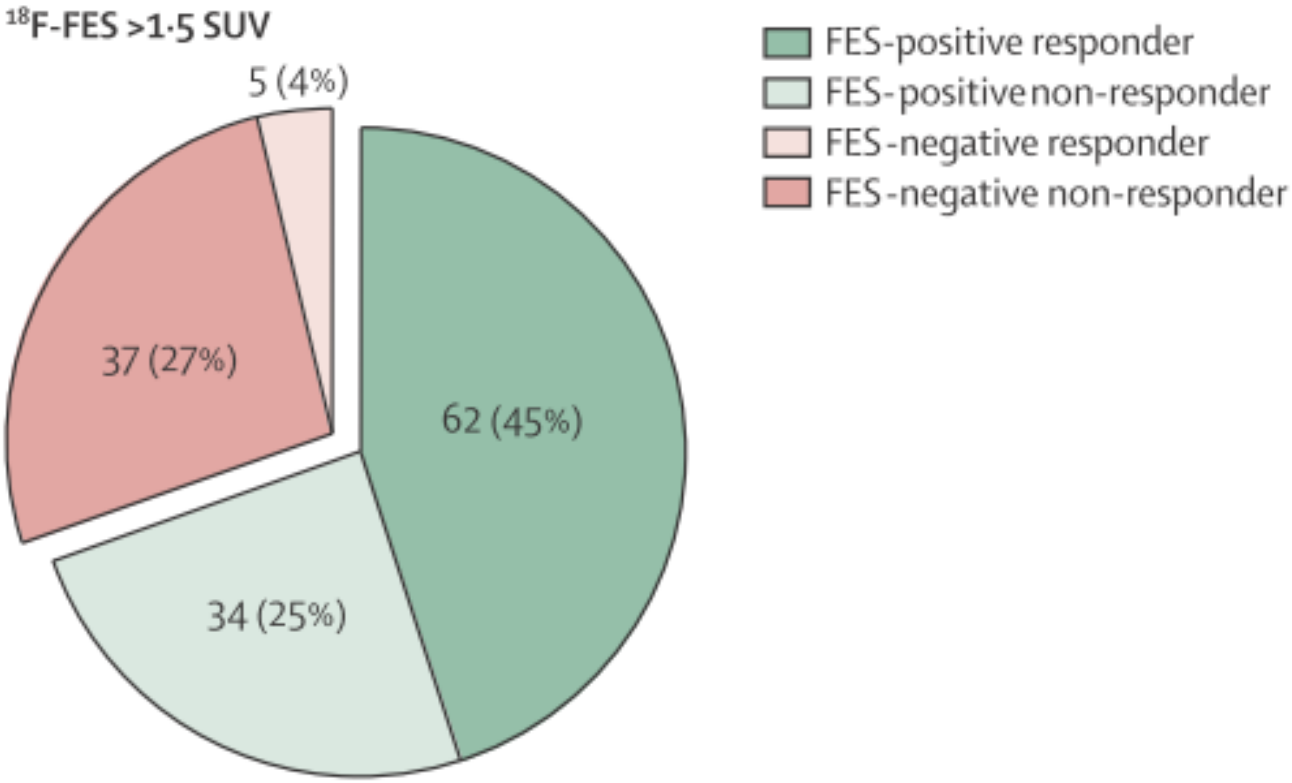

Figure 4: Predictive value of ^{18}F-FES-PET (n=138 patients)

van Kruchten M, *Lancet Oncol* 2013;14:e465-75

Etude ESTROTEPREDIC

- PHRC (Dr Khaldoun Kerrou)
- Objectif principal: Evaluer la valeur prédictive de la réponse à l'hormonothérapie de la TEP au FES chez des patientes présentant un cancer du sein métastatique ER+.

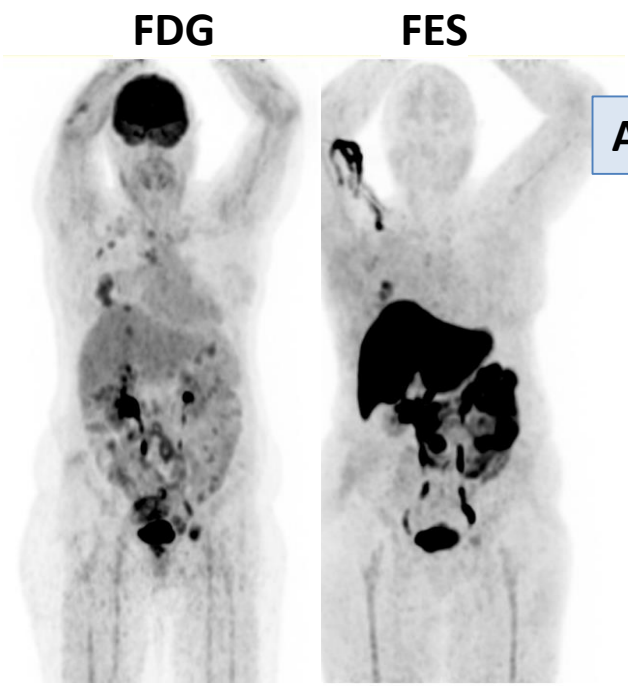

Toutes lésions FDG+/FES+ → **TEP FES « positive »**

Au moins une lésion FDG+/FES- → **TEP FES « négative »**

Analyse visuelle:

Sensibilité	**73%**
Spécificité	**65%**
Valeur prédictive positive	**41%**
Valeur prédictive négative	**88%**

Prédiction de la réponse à l'hormonothérapie: rôle du « metabolic flare »

TEP FDG et TEP FES avant et après <u>7-10 jours</u> de traitement par tamoxifene

↗ métabolisme tumoral (« metabolic flare ») chez les patients répondeurs → **Bonne VPP**

↘ FES chez tous les patients (compétition du tamoxifene)

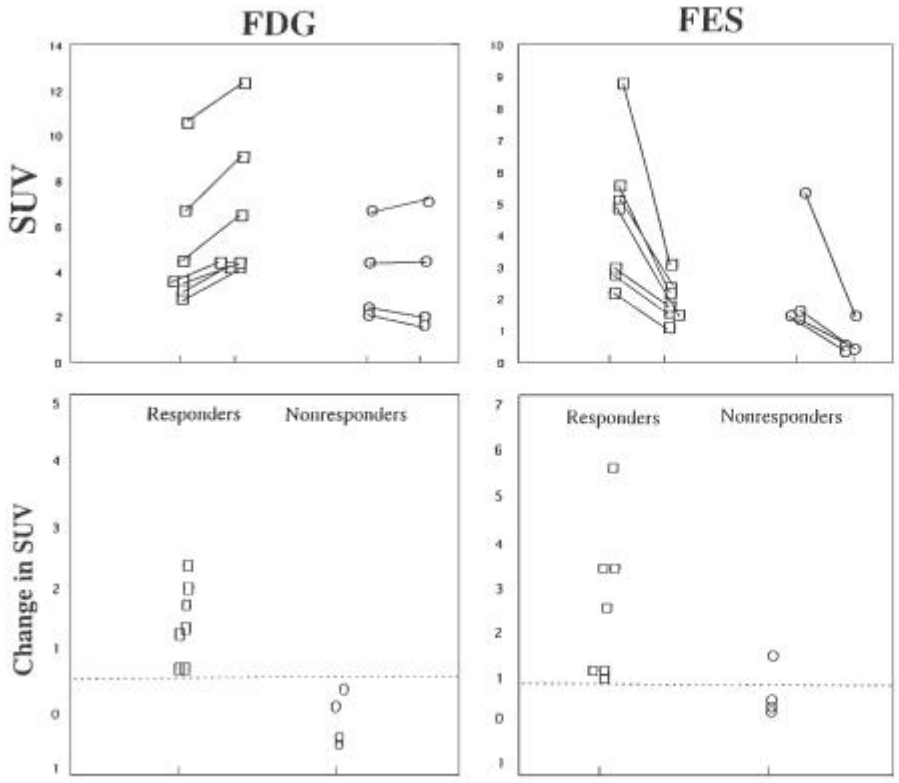

Fig. 1. The tumor SUVs for FDG and FES before and after tamoxifen treatment for the seven patients who responded to treatment and the four who did not (*upper panels*). The absolute changes in SUVs (pretreatment to post-treatment) are shown in the *lower panels*

Dehdashti F, *Eur J Nucl Med* 1999;26:51-56

Disponibilité résiduelle des ER sous fulvestrant

TEP FES avant et après 28 jours de traitement par fulvestrant

Fixation « résiduelle » de FES à 28 jours → progression précoce

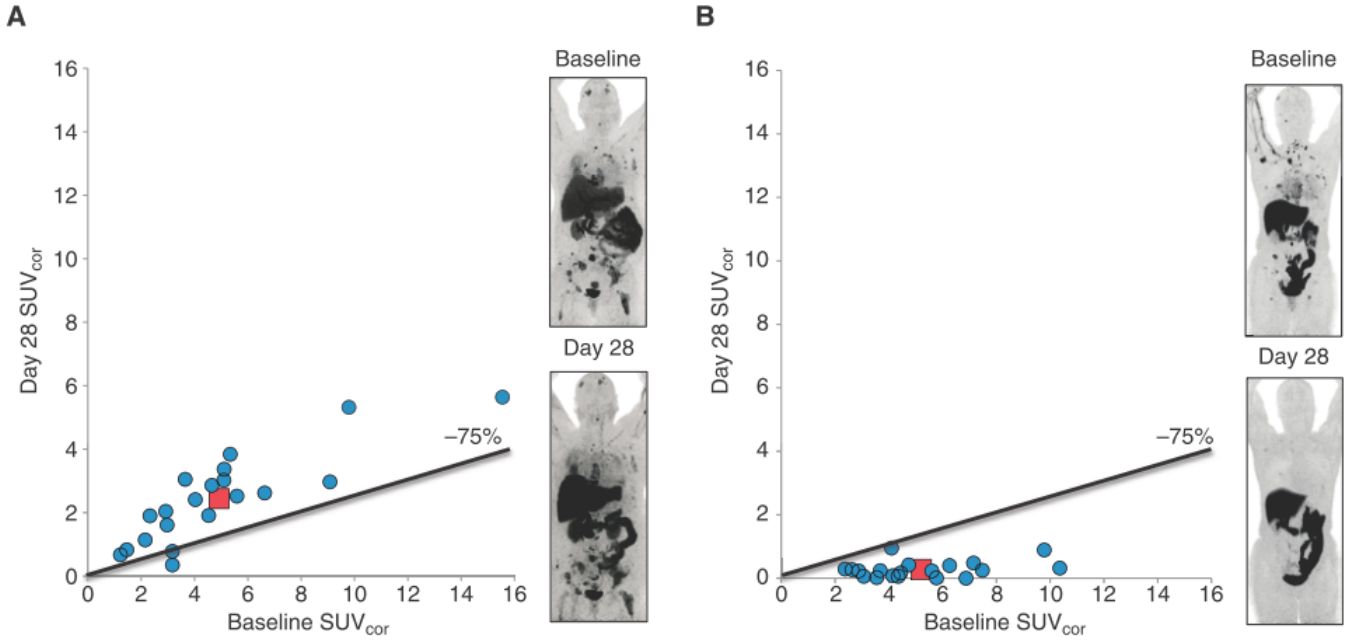

Figure 1. Change in FES uptake in the tumor during fulvestrant treatment. **A,** a representative patient with incomplete reduction in FES uptake. **B,** a patient with extensive reduction in FES uptake. Blue dots indicate individual lesions; the red square represents the median of all lesions used for patient-based analysis. At the right side of the plot the corresponding PET images are shown. The line indicates the 75% reduction threshold.

Place de la TEP au FES dans les nouvelles stratégies thérapeutiques?

The cyclin-dependent kinase 4/6 inhibitor palbociclib in combination with letrozole versus letrozole alone as first-line treatment of oestrogen receptor-positive, HER2-negative, advanced breast cancer (PALOMA-1/TRIO-18): a randomised phase 2 study

Lancet Oncol 2015; 16: 25–35

Richard S Finn, John P Crown, Istvan Lang, Katalin Boer, Igor M Bondarenko, Sergey O Kulyk, Johannes Ettl, Ravindranath Patel, Tamas Pinter, Marcus Schmidt, Yaroslav Shparyk, Anu R Thummala, Nataliya L Voytko, Camilla Fowst, Xin Huang, Sindy T Kim, Sophia Randolph, Dennis J Slamon

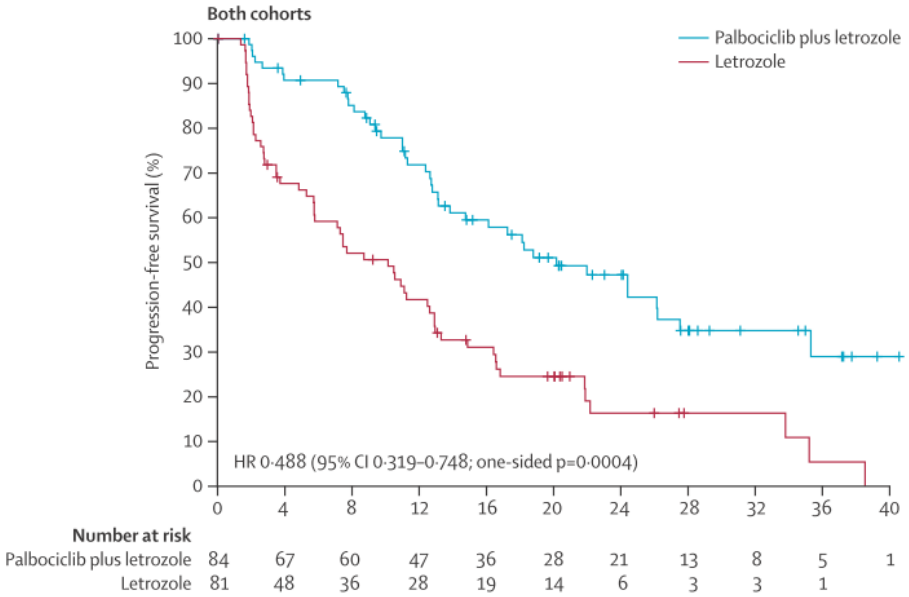

Association hormonothérapie + inhibiteur CDK4/6 (inhibe synthèse d'ADN)
→ effet synergique

Quel effet sur les lésions FES- ?

Place de la TEP au FES dans les nouvelles stratégies thérapeutiques?

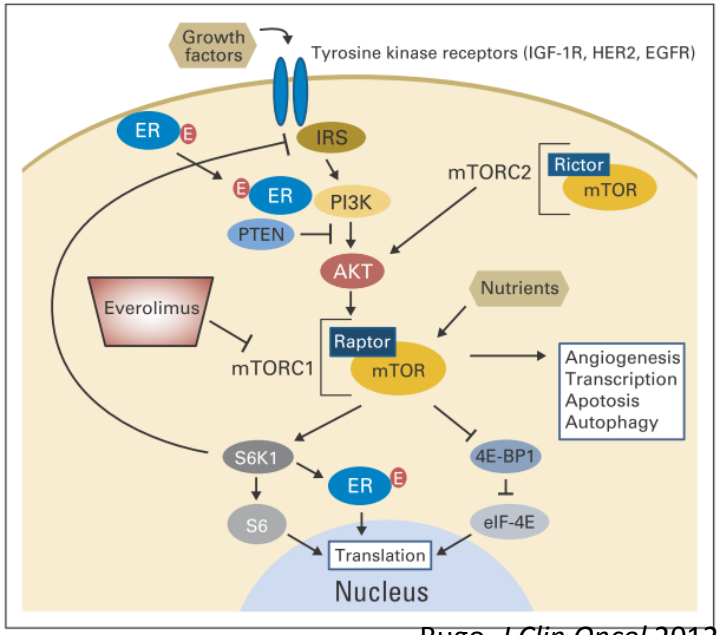

Rugo, *J Clin Oncol* 2012

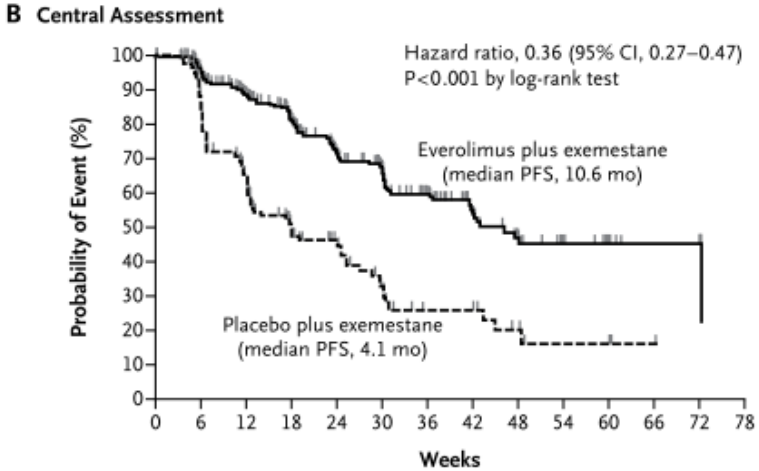

The NEW ENGLAND JOURNAL of MEDICINE

ORIGINAL ARTICLE

Everolimus in Postmenopausal Hormone-Receptor–Positive Advanced Breast Cancer

José Baselga, M.D., Ph.D., Mario Campone, M.D., Ph.D., Martine Piccart, M.D., Ph.D., Howard A. Burris III, M.D., Hope S. Rugo, M.D., Tarek Sahmoud, M.D., Ph.D., Shinzaburo Noguchi, M.D., Michael Gnant, M.D., Kathleen I. Pritchard, M.D., Fabienne Lebrun, M.D., J. Thaddeus Beck, M.D., Yoshinori Ito, M.D., Denise Yardley, M.D., Ines Deleu, M.D., Alejandra Perez, M.D., Thomas Bachelot, M.D., Ph.D., Luc Vittori, M.Sc., Zhiying Xu, Ph.D., Pabak Mukhopadhyay, Ph.D., David Lebwohl, M.D., and Gabriel N. Hortobagyi, M.D.

Association exemestane + everolimus (inhibe mTOR) après echec des anti-aromatases

Disponibilité des ER après anti-aromatases ?

TEP au FES pour guider la radiothérapie stéréotaxique? (maladie oligométastatique)

Stereotactic Body Radiation Therapy (SBRT) guided by 16α-[^{18}F]-fluoro-17β-oestradiol (FES) PET/CT in addition to first-line systemic endocrine therapy in patients with metastatic breast cancer: a pilot study

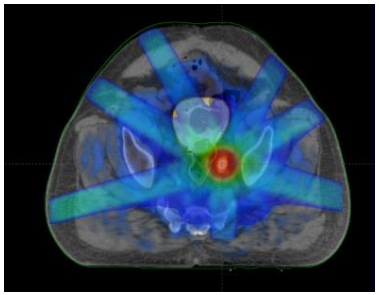

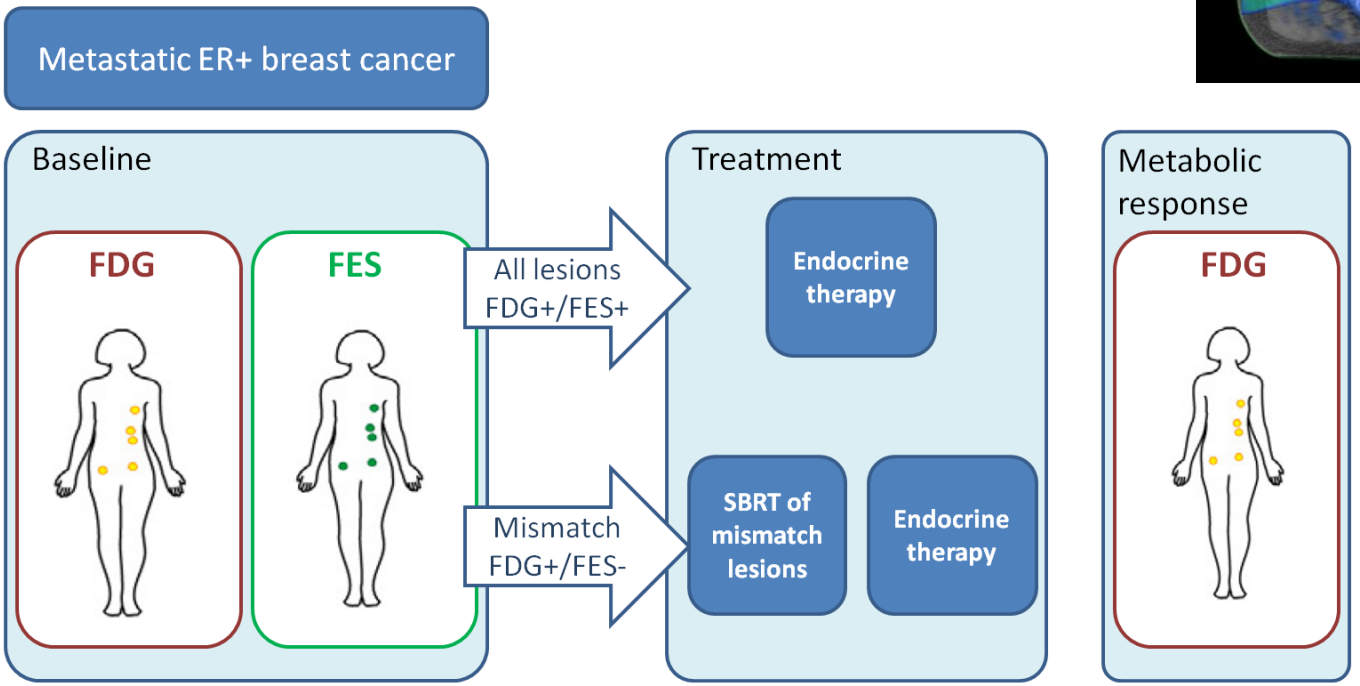

Imagerie d'HER2

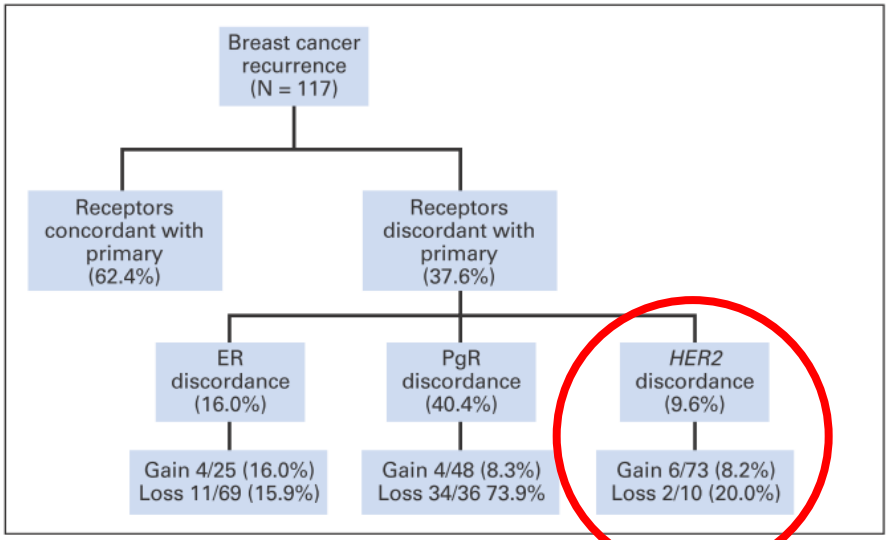

Fig 2. Changes in estrogen receptor (ER), progesterone receptor (PgR), and *HER2* between the original pathology report of the primary tumor and the metastasis.

Amir E, *J Clin Oncol* 2011;30:587-592

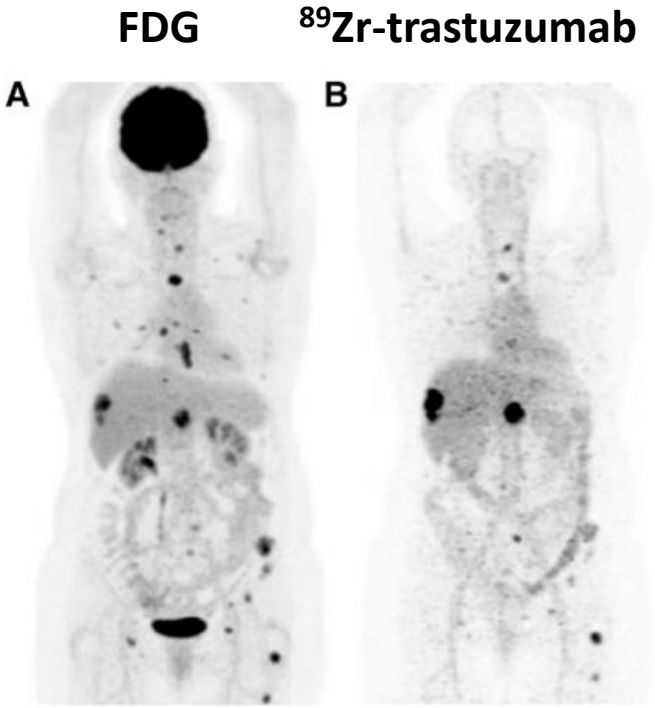

Gebhart G, *J Nucl Med* 2016;57:81S-88S

Imagerie d'HER2

HER2 imaging with ^{111}In-Trastuzumab / Pertuzumab

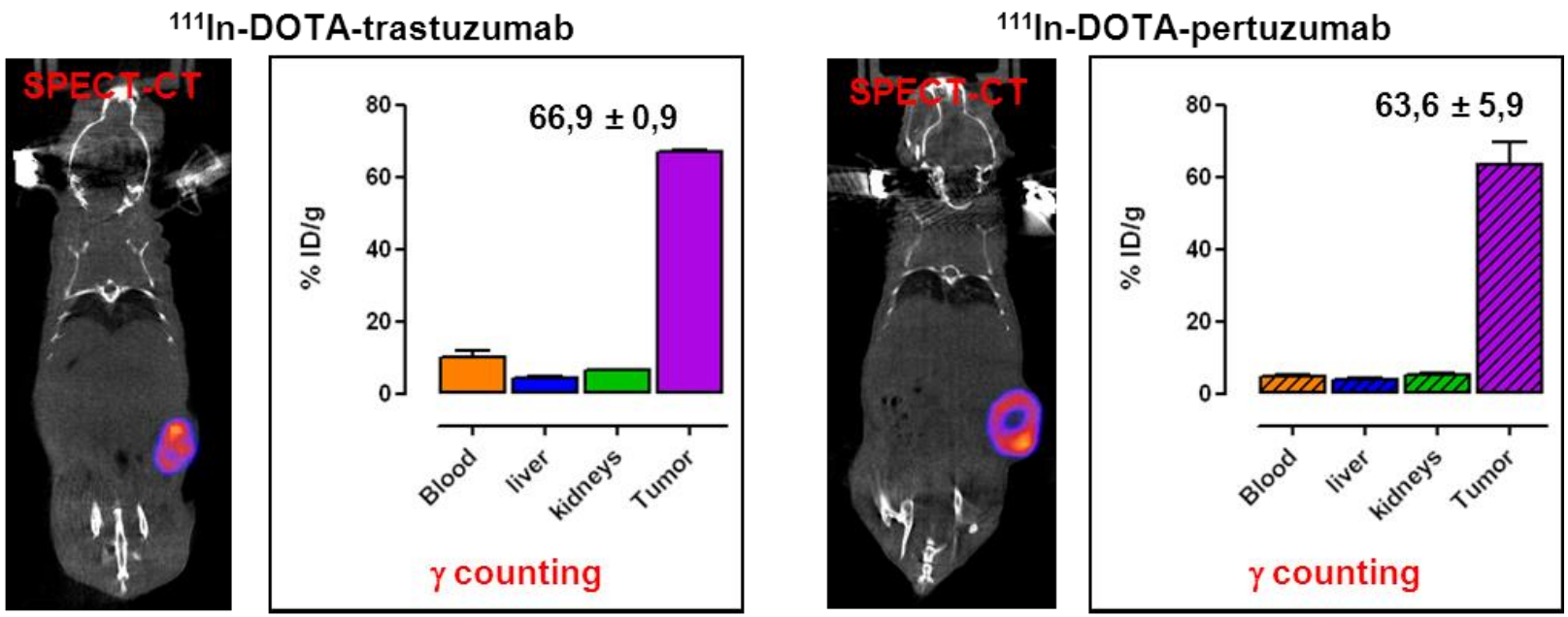

=> Lower efficacy of pertuzumab in HER2+ breast cancer does not seem to be due to lower target binding

Collin *et al., SABCS 2012* – Oudot *et al., EORTC 2012*

Etude ZEPHIR

^{89}Zr-trastuzumab (TEP HER2) et FDG pour prédire la réponse à TDM-1 après échec du trastuzumab (cancers du sein métastatiques HER2+)

TEP HER2 et FDG avant traitement; TEP FDG après 1ère cure

TEP HER2+

(71%)

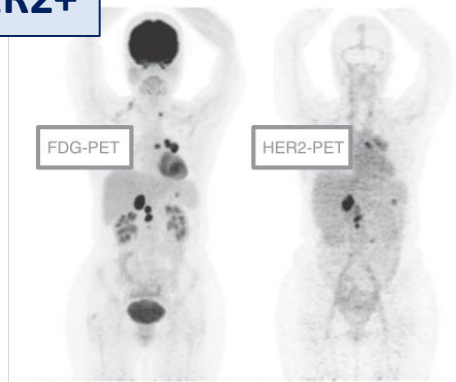

Right adrenal gland, lymph node + gastric involvement seen on both FDG-PET and HER2-PET

TEP HER2-

(29%)

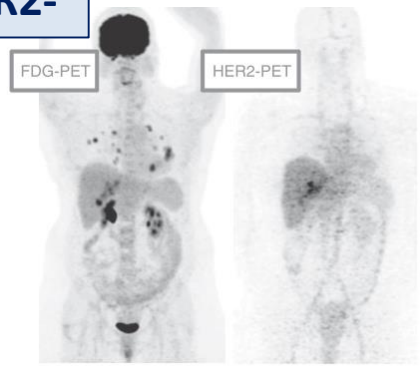

Liver + lung involvement seen on FDG-PET: most of tumor load not seen on HER2-PET, positive uptake in the liver only

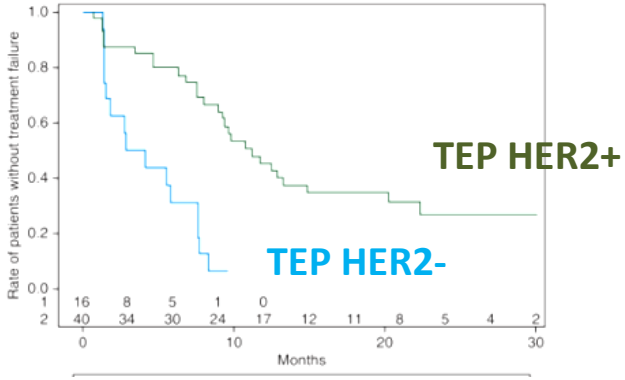

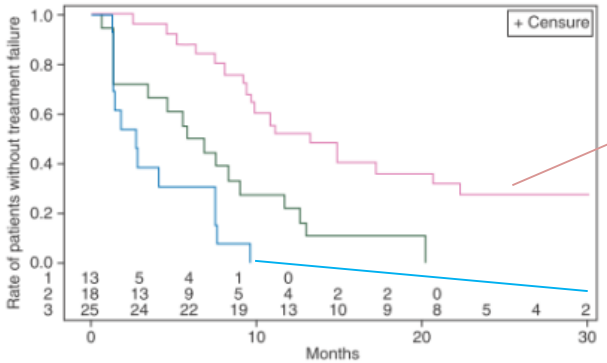

TEP HER2+
Bonne réponse métabolique

TEP HER2-
mauvaise réponse métabolique

Gebhart G, *Ann Oncol* 2016;27:619-624

Imagerie d'HER2

Antibodies for imaging purposes

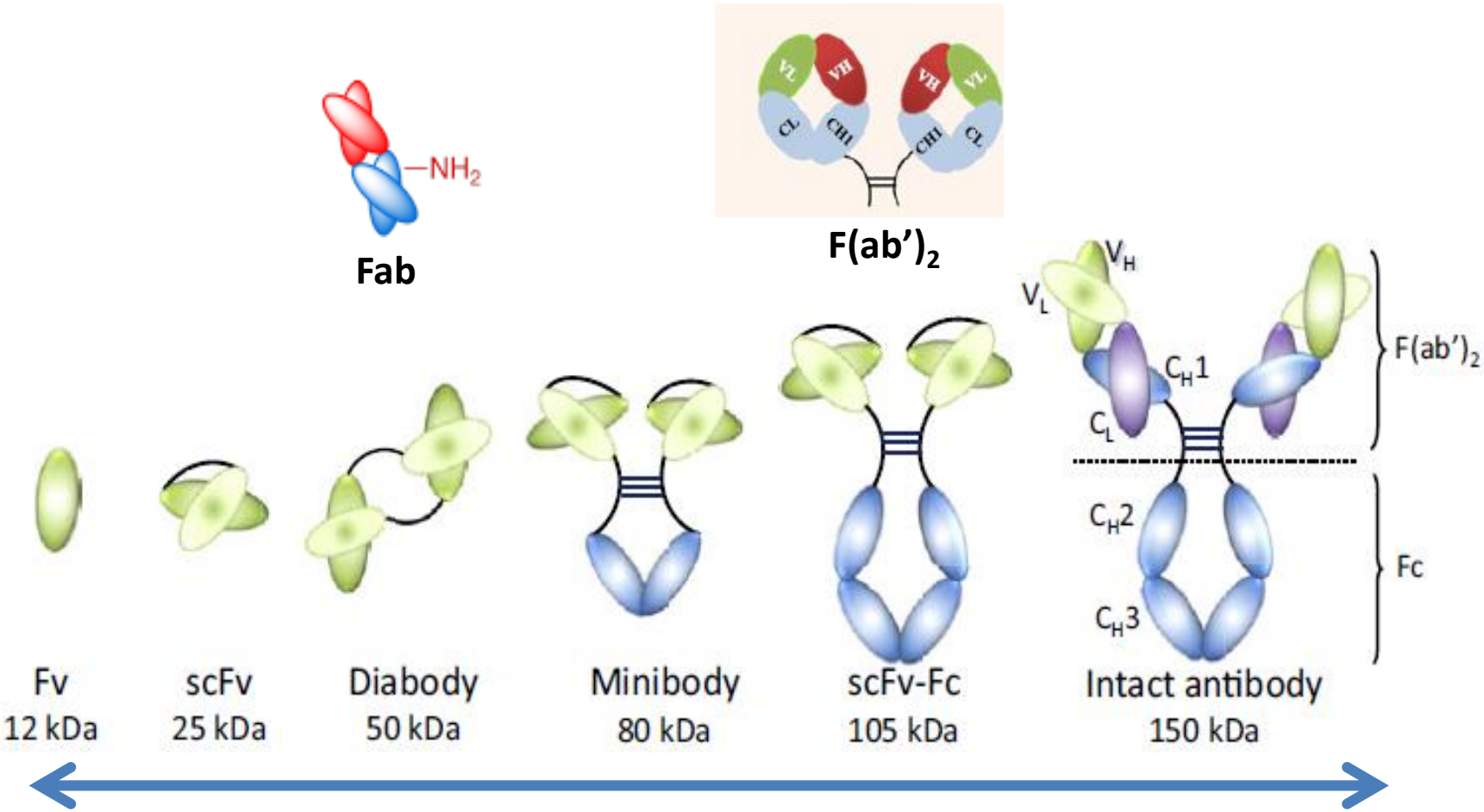

Adapted from Olafsen et Wu, *Semin Nucl Med* 2010;40:167-181

HER2: approche théranostique

Association d'un même vecteur (anticorps ou fragment d'anticorps) avec:

Un isotope à usage <u>diagnostique</u>
(^{18}F, ^{68}Ga, ^{64}Cu, ^{89}Zr…)

Un isotope à usage <u>thérapeutique</u>
(^{177}Lu, ^{90}Y, ^{225}Ac, ^{188}Re, …)

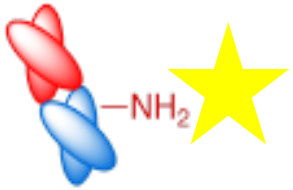

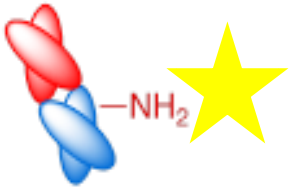

Imagerie multimodalités

Imagerie de la prolifération tumorale (directe ou indirecte)

^{18}F-FDG

^{18}F-FLT

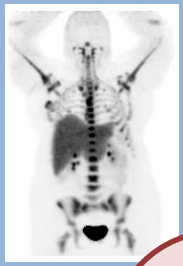

IRM

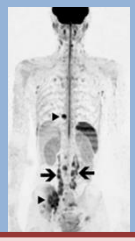

Imagerie des récepteurs

^{89}Zr-trastuzumab

^{18}F-FES

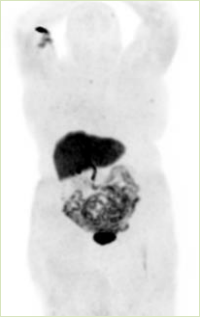

TEP/IRM

Autres traceurs

ER, HER2, EGFR…

Métabolisme
(^{18}F-FDG, ^{18}F-FCH)

Infiltrat lymphocytaire
(^{89}Zr-antiCD8)

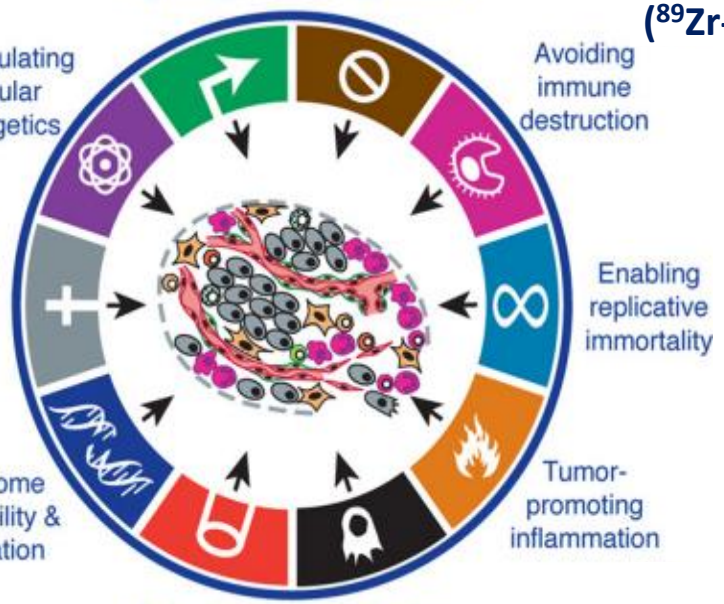

Apoptose
(^{99m}Tc-annexin)

Prolifération
(^{18}F-FLT)

Angiogénèse
(^{89}Zr-bevacizumab)

Hypoxie
(^{18}F-FMISO)

Hanahan D, *Cell* 2010;646-74

Conclusion

Fort développement présent et à venir de l ’imagerie moléculaire, mais:

- Indications encore à préciser (études multicentriques)
- Déploiement de ces nouvelles techniques, efforts de standardisation
- Intégration dans les nouvelles stratégies diagnostiques (biomarqueurs, génomique) ?