Comment faire une synthèse chirurgicalement utile d'un dossier d'imagerie complexe

G. Hurtevent-Labrot

S. Ferron, M. Asad-Syed

SFSPM - Lille - 10 Novembre 2017

Problématique chirurgicale

- Identification des lésions à opérer : bilan radiologique exhaustif
  - Localisation précise
  - Nombre : la complexité du dossier en dépend
  - Taille lésionnelle, inter-lésionnelle, extension globale
  - Preuve histologique pour chaque lésion

- Décision thérapeutique : MP / MT / Oncoplastie, GS / Curage
  - Taille lésionnelle / volume mammaire
  - Topographie : proximité PAM, muscle pectoral, peau
  - Statut ganglionnaire : imagerie +/- histologie (cytoponction / microbiopsie)

- But : Chirurgie en 1 temps en marges saines en étant le plus conservateur possible

Connaissances du radiologue

- Techniques opératoires
  - Chirurgie du plan cutané au plan pectoral
    - Mesures intéressantes à communiquer au chirurgien : hauteur / largeur
  - Exérèse monobloc privilégiée (lésion bifocale)
    - Extension lésionnelle totale

- Définitions variables dans la littérature
  - Multifocalité : dans le même quadrant ou distance entre 2 lésions ≤ 3/5 cm
  - Multicentricité : 2 quadrants distincts ou distance entre 2 lésions ≥ 3/5 cm

- Connaissances thérapeutiques
  - K du sein +++, lésions à risque, lésions bénignes
  - Indications MT / MP / Oncoplastie, GS / CA, chirurgie première ou CT néo-adjuvante

- Prises en compte des lésions qui modifient la chirurgie : dialogue

- Pour chaque lésion Mg / US / IRM : cartographie précise
  - Quadrant, rayon horaire, profondeur, distance au mamelon
  - Taille : grand axe, surtout largeur et hauteur

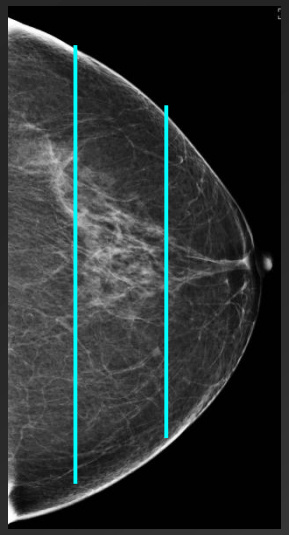

- Distance(s) inter-lésionnelle(s)

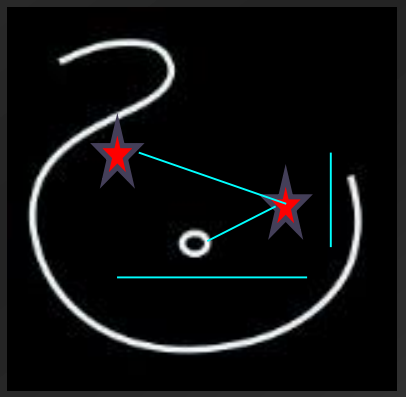

- Etendue lésionnelle globale
  - Diamètre transverse et hauteur
  - Reconstructions MIP/MPR en IRM

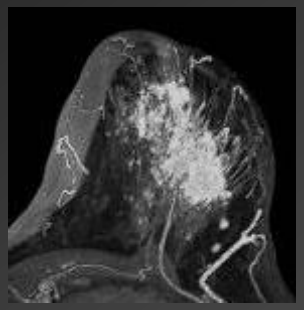

- Etude ganglionnaire
  - Morphologie / nombre

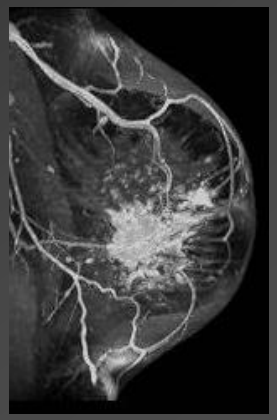

- Choix des cibles et du mode de prélèvement
  - Preuve histologique systématique
  - Pose de clip : lésion subtile, concordance entre Mg / US / IRM, facilite le travail du chirurgien
- Synthèse du bilan d'imagerie / Schéma

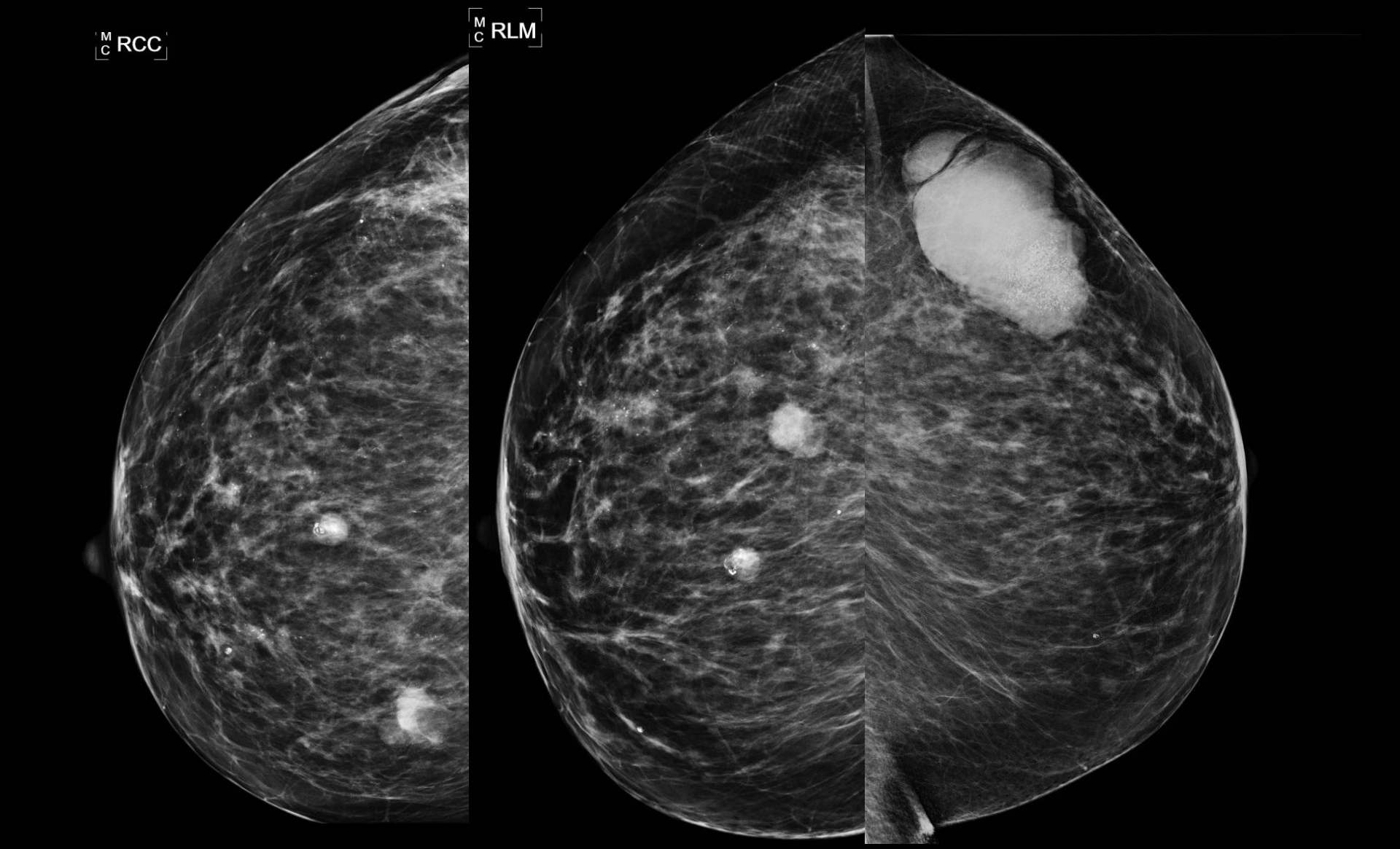

- Patiente adressée pour volumineuse masse du QSE du sein G
- Sein D : masses et microcalcifications

Ext

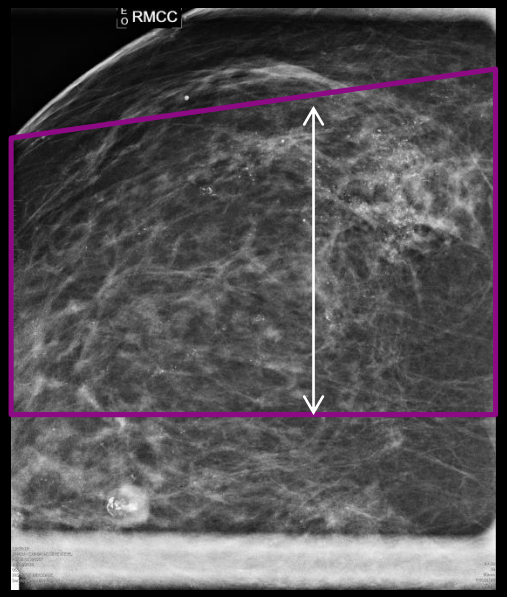

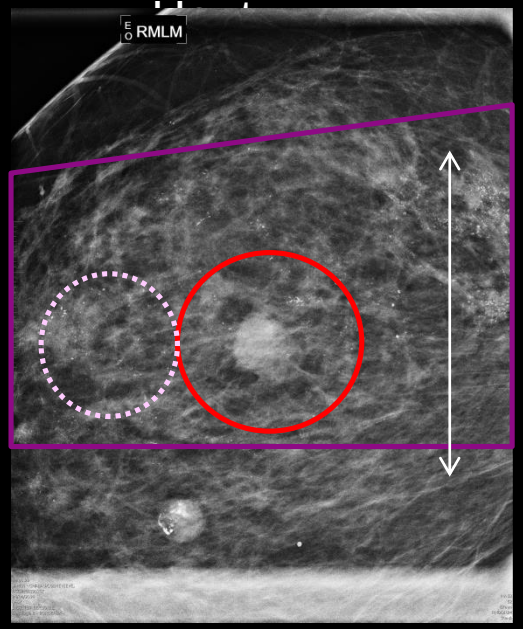

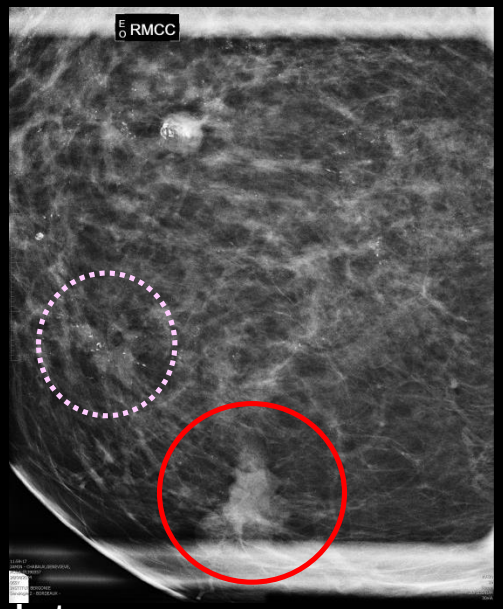

Int

Sein D

- Micro très étendues (Ag)
- Masses additionnelles
- Topographie/extension des lésions
  - Micro ACR 5 QSE étendues
  - Masse ACR 5 QSI
  - Micro ACR 4 QSI

- But : choisir des sites de prélèvements per-cutanés
- Toujours penser à l'éventuelle thérapeutique
- Preuve histologique systématique
- Ne pas hésiter à en discuter en RCP

Sein D

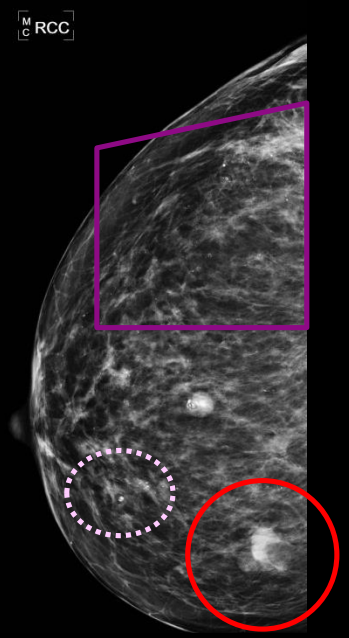

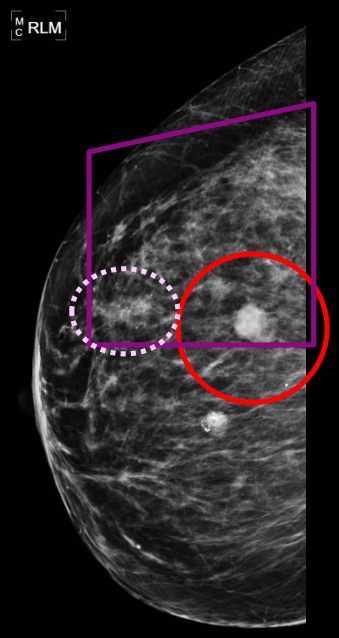





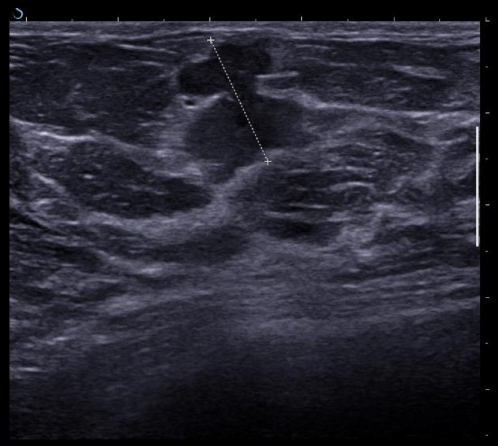

- Macrobiopsies sous stéréotaxie QSE CCIS de grade intermédiaire
- Microbiopsies sous écho QSI CCI de grade 2

- Décision de mastectomie totale : 2 lésions malignes distantes
- Si la masse n’avait pas été maligne : échantillonnage nécessaire des micro du QSI

Sein G

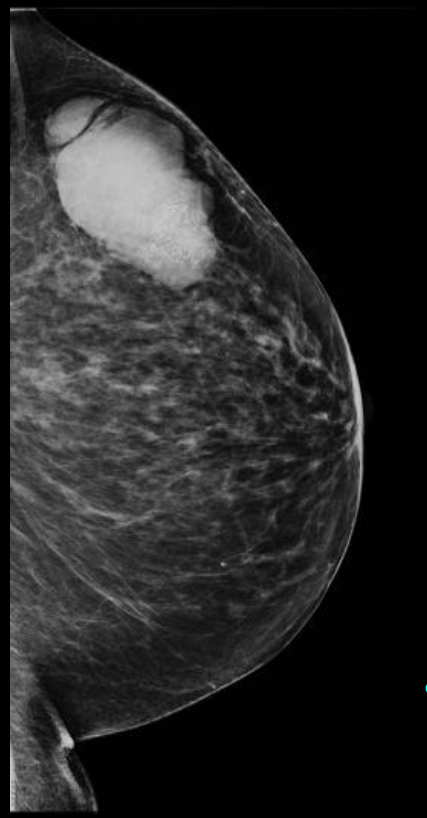

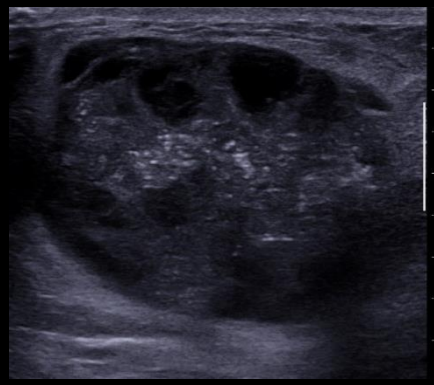

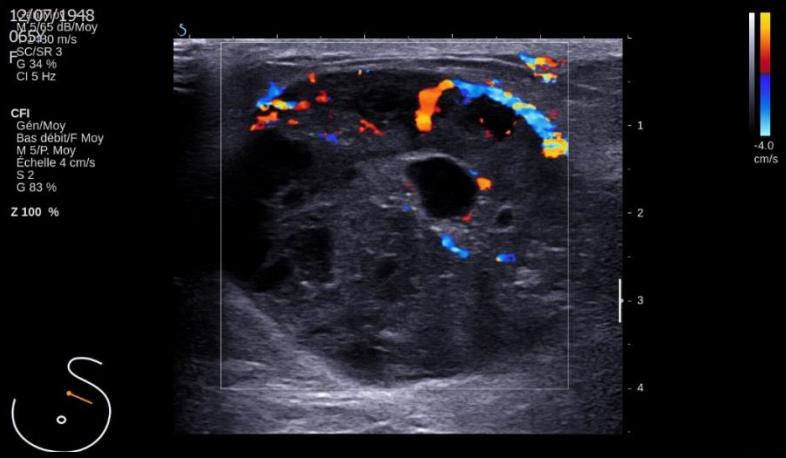

- Microbiopsies sous écho : Tumeur phyllode de grade

- Décision de tumorectomie

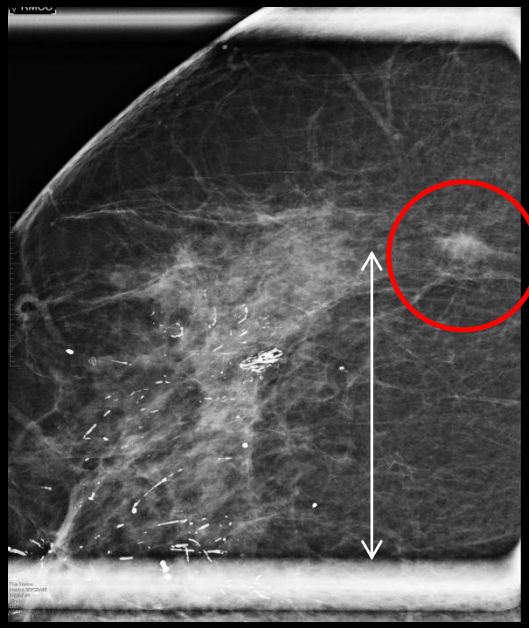

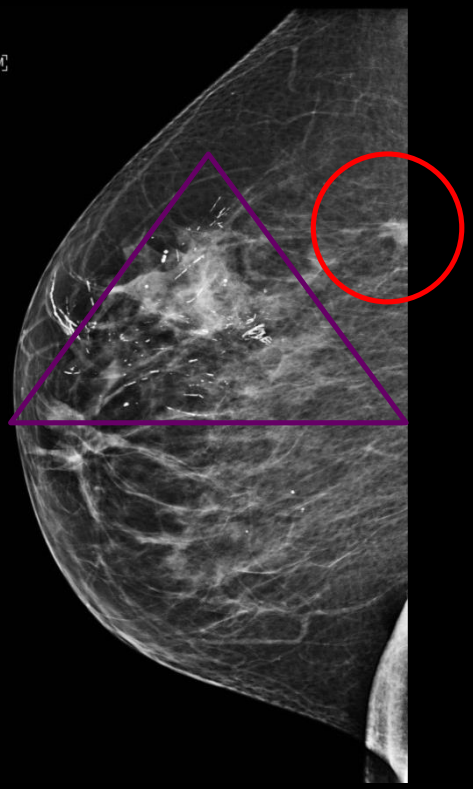

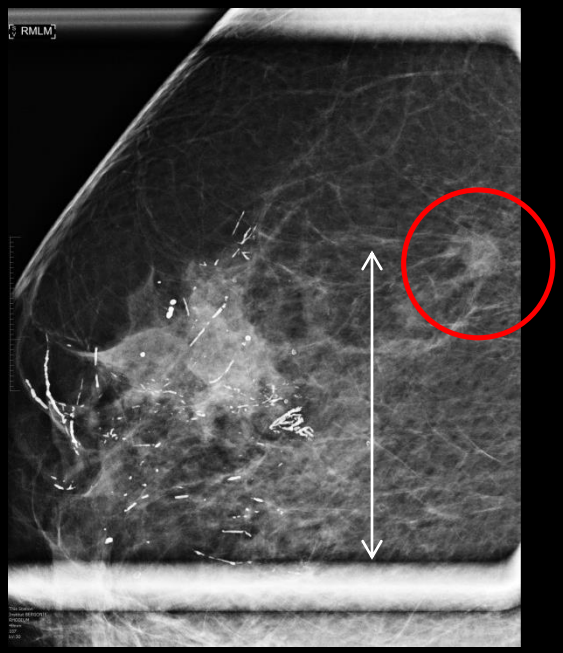

- Masse ACR5 du QSE : taille
- Microcalcifications QSE
  - Extension : hauteur et largeur
  - Distance / PAM

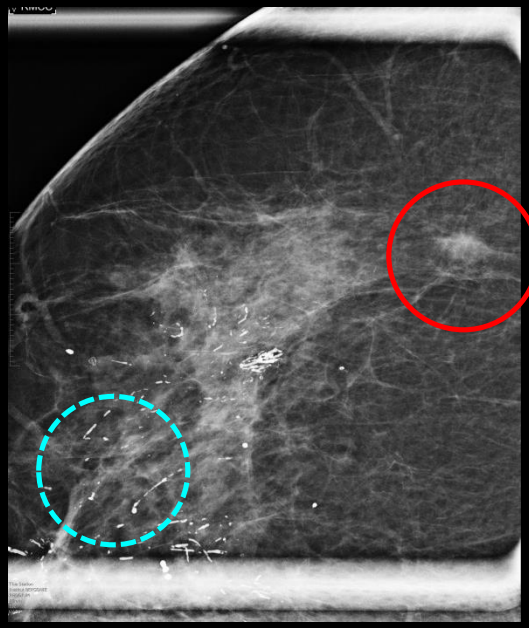

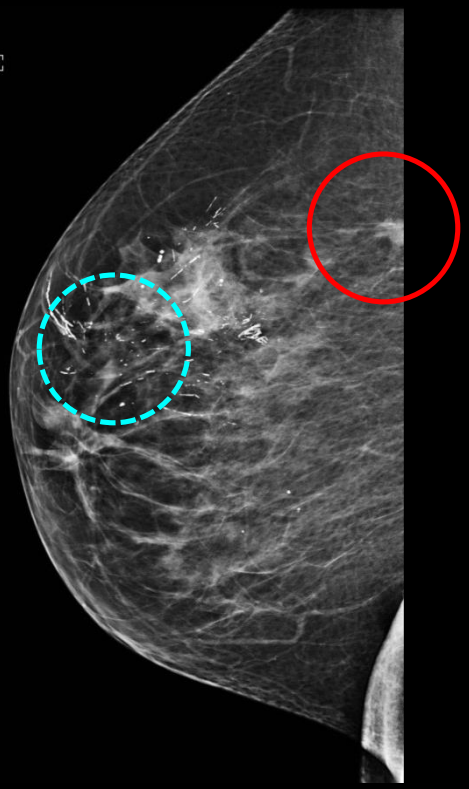

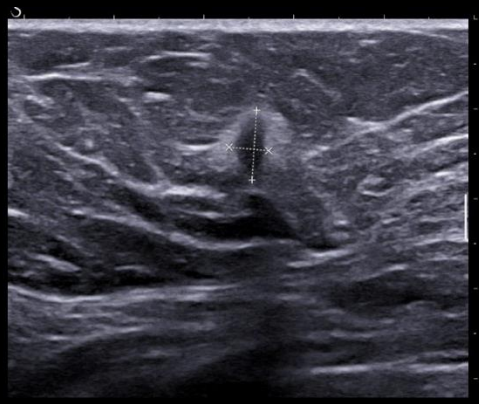

- Décision type et localisation des prélèvements
- Microbiopsies sous écho de la masse : CCI grade 2
- Macrobiopsies sous stéréotaxie des micro
  - Site distant de la masse et proche de la PAM : compromis entre éloignement et VVP de malignité
  - CCIS de haut grade
- Pose de clip : concordance Mg / US et site des biopsies dans plage de micro

- Décision chirurgicale : MP avec retrait de la PAM et oncoplastie
- Discussion avec le chirurgien des modalités de repérage préopératoire
  - Nombre et sites des harpons

- Patiente adressée pour avis sur micro QSE Sein G

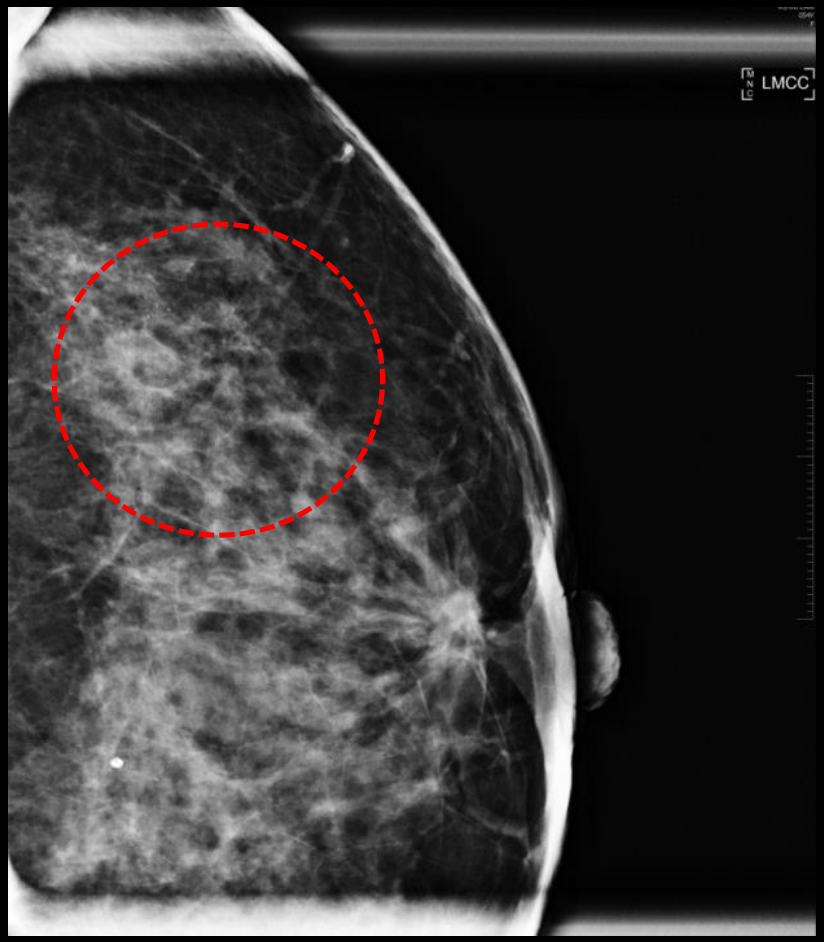

- Agrandissements F et P
- Autre(s) lésion(s)?

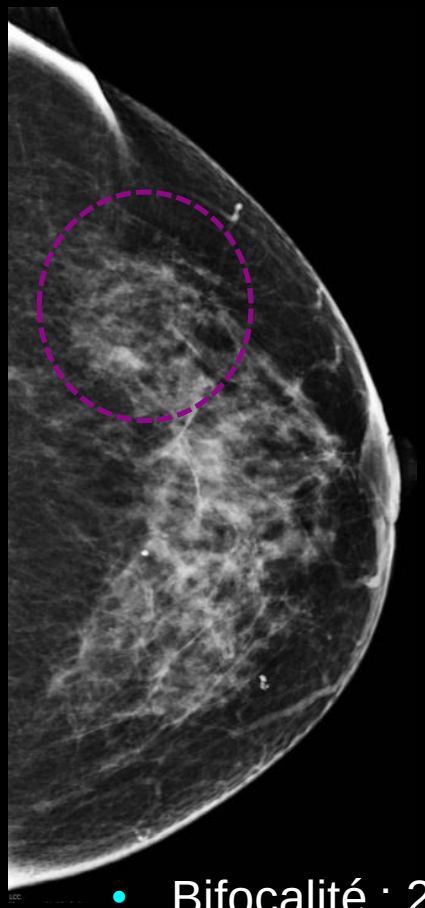

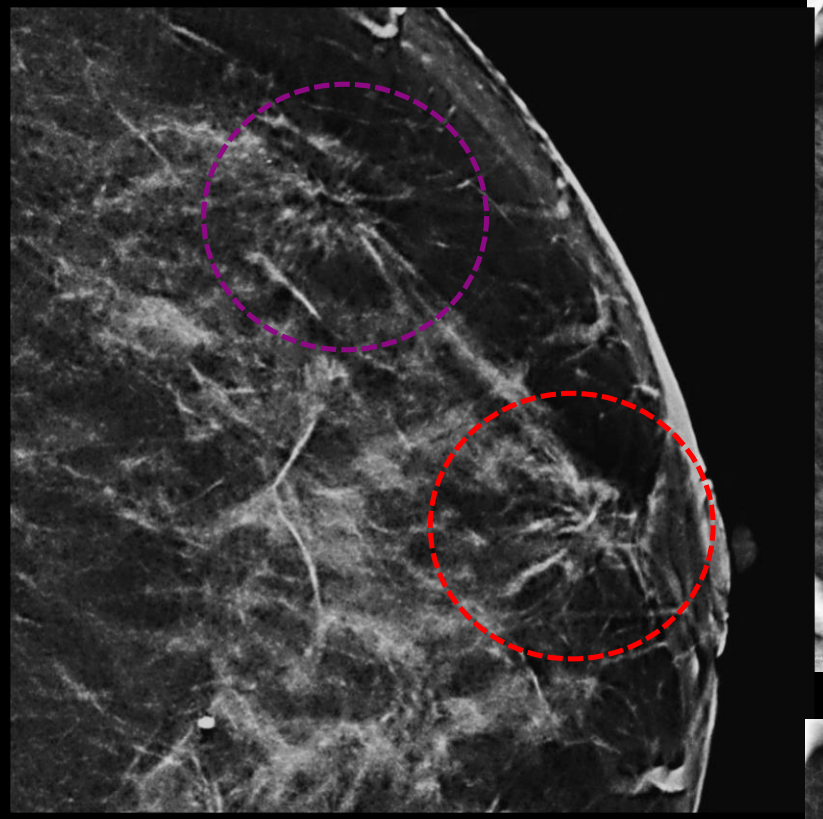

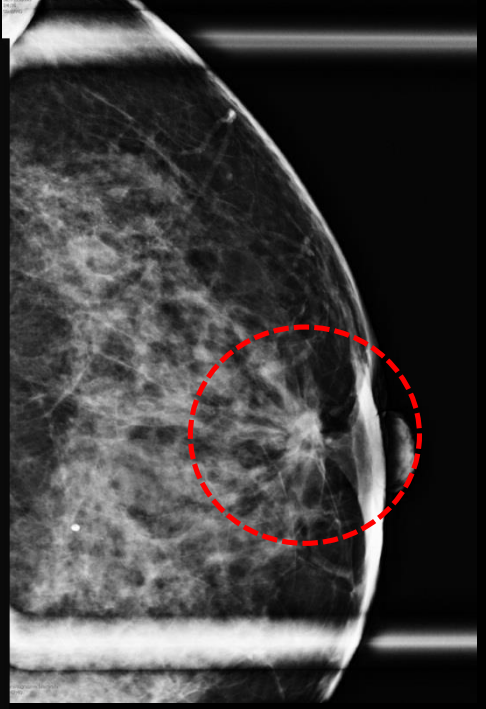

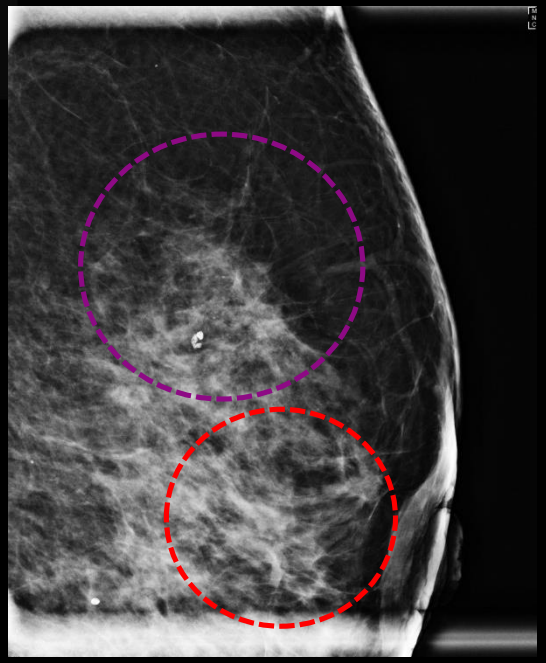

- Bifocalité : 2 masses ACR 5
- Topographie
  - QSE et RA
  - Distance / PAM
- Extension lésionnelle
  - Taille de chacune des masses
  - Distance entre les lésions
  - Etendue globale

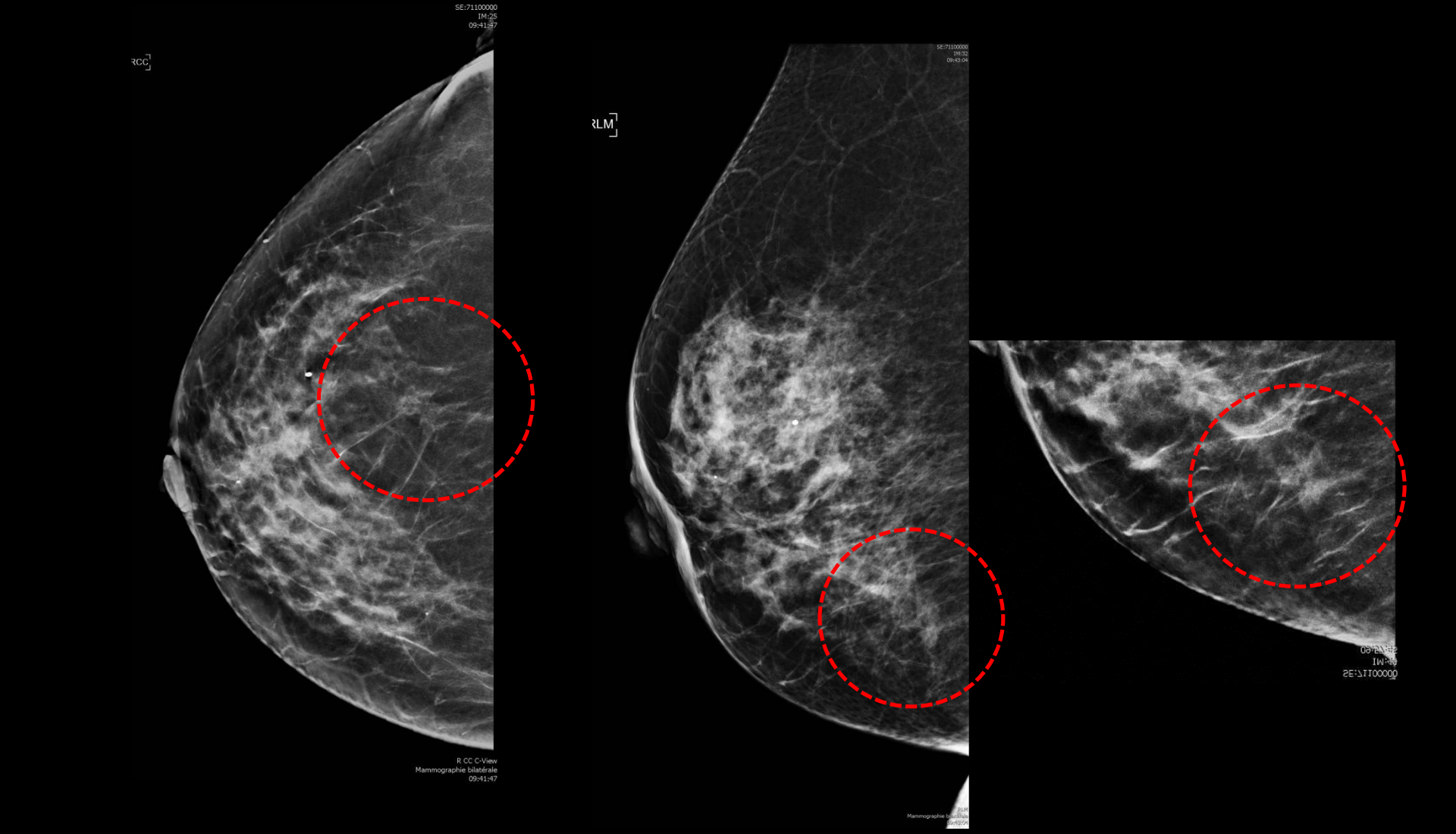

- Bilatéralité
- Masse ACR 5 QIE Sein D

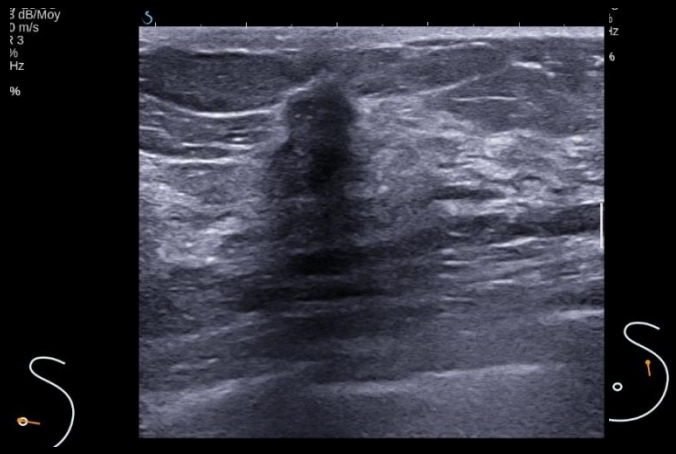

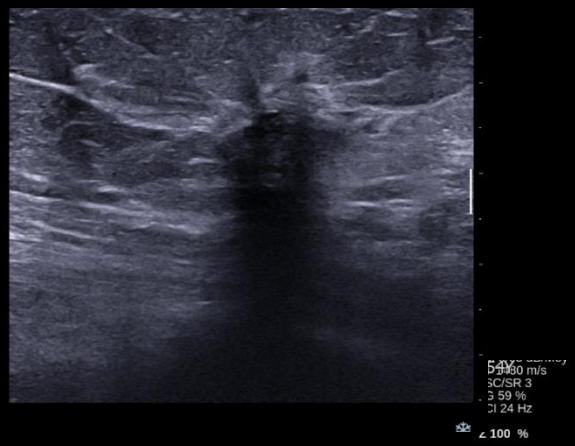

- Masse ACR 5 RA et QSE : CCI grade I

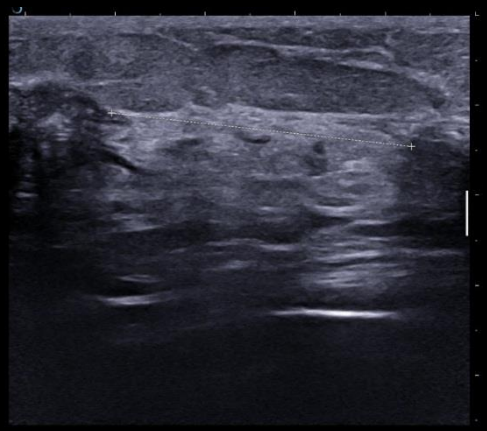

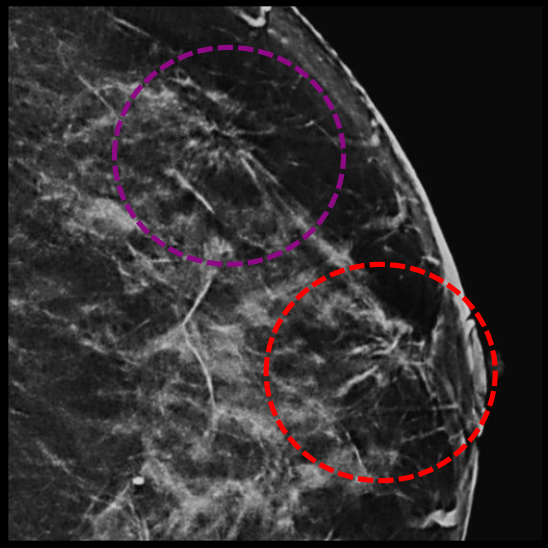

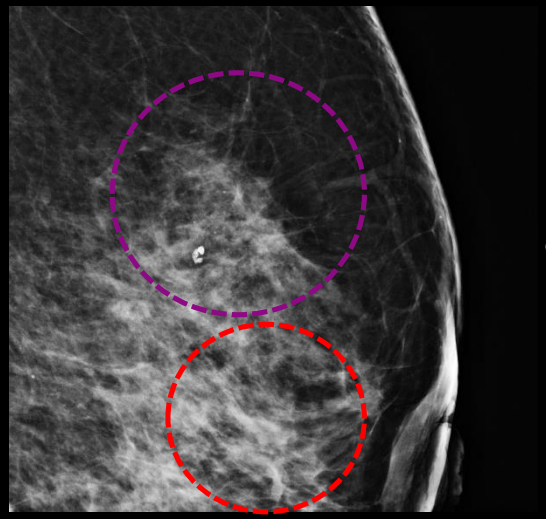

- Distance inter-lésionnelle : 3cm

- Quadrantectomie après double repérage sous échographie

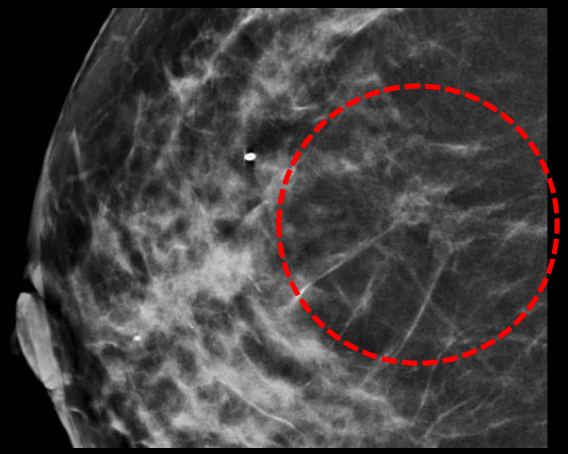

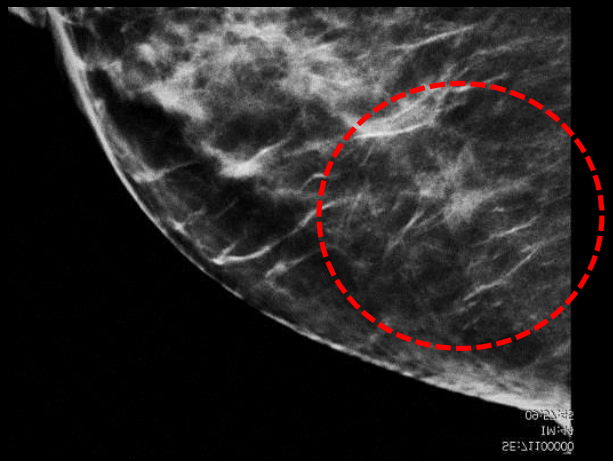

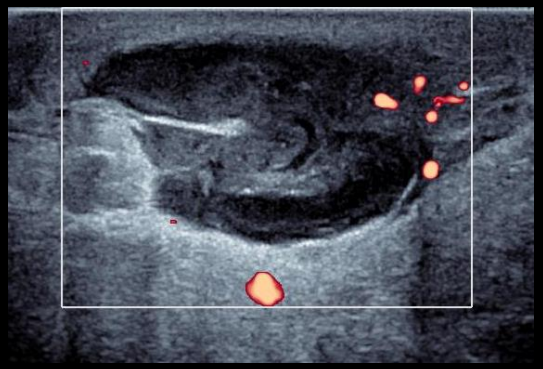

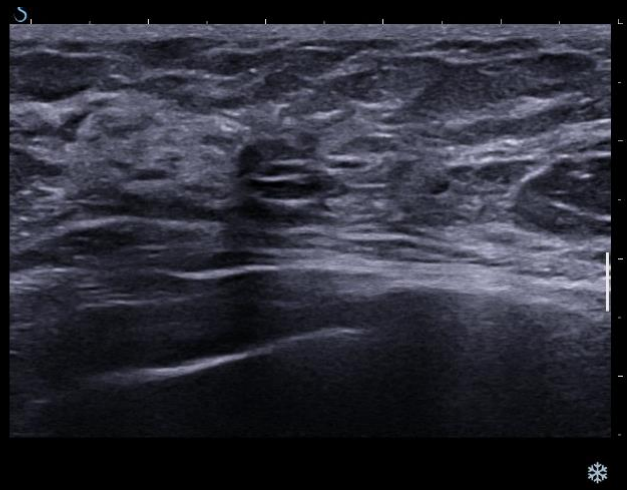

- Microbiopsies sous écho avec pose de clip : CCI grade II
- Etude ggl : adénomégalie suspecte : biopsie positive (pas de GS)
- MP après repérage sous échographie et CA

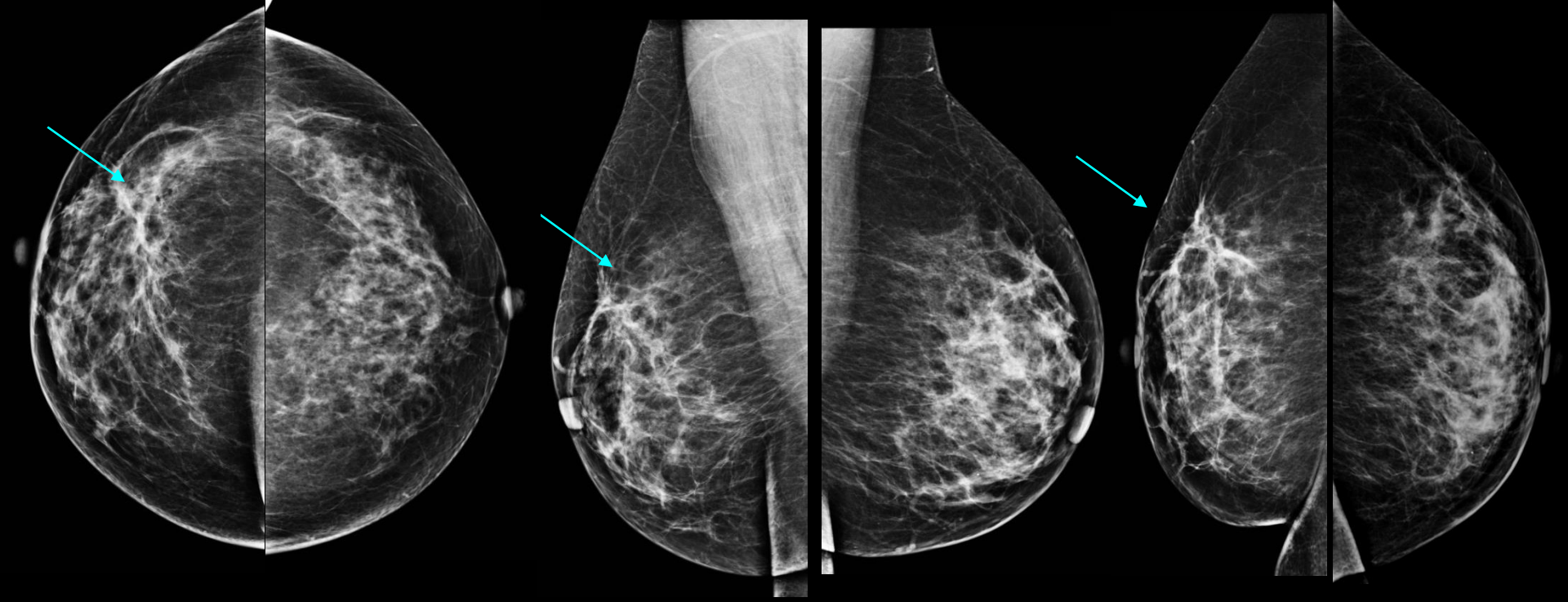

Sein D CLI prouvé

- Distorsion architecturale QSE
- Plage hypoéchogène
- Taille difficile à évaluer en technique std

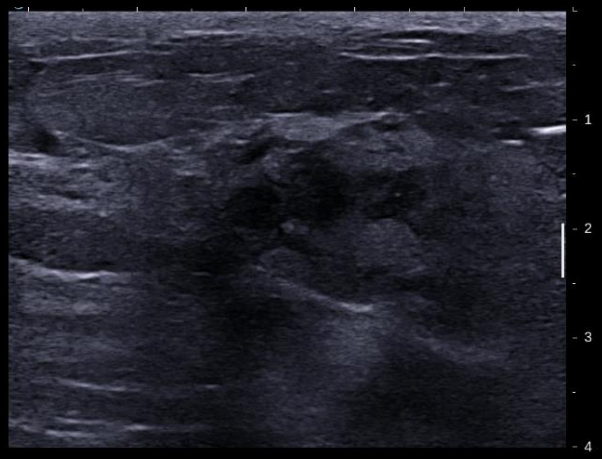

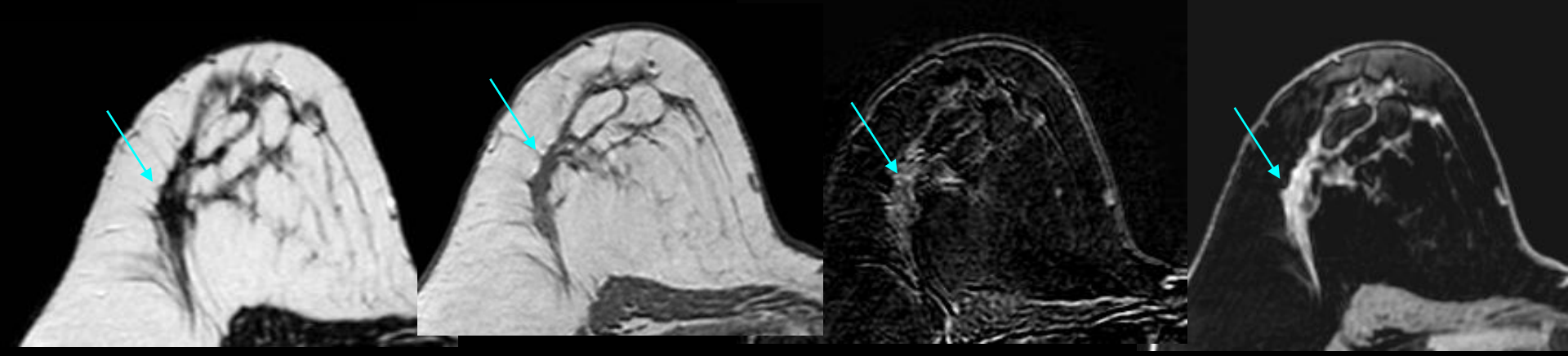

T2 | T1 Sans injection | Soustraction | Tardive injectée Fat Sat

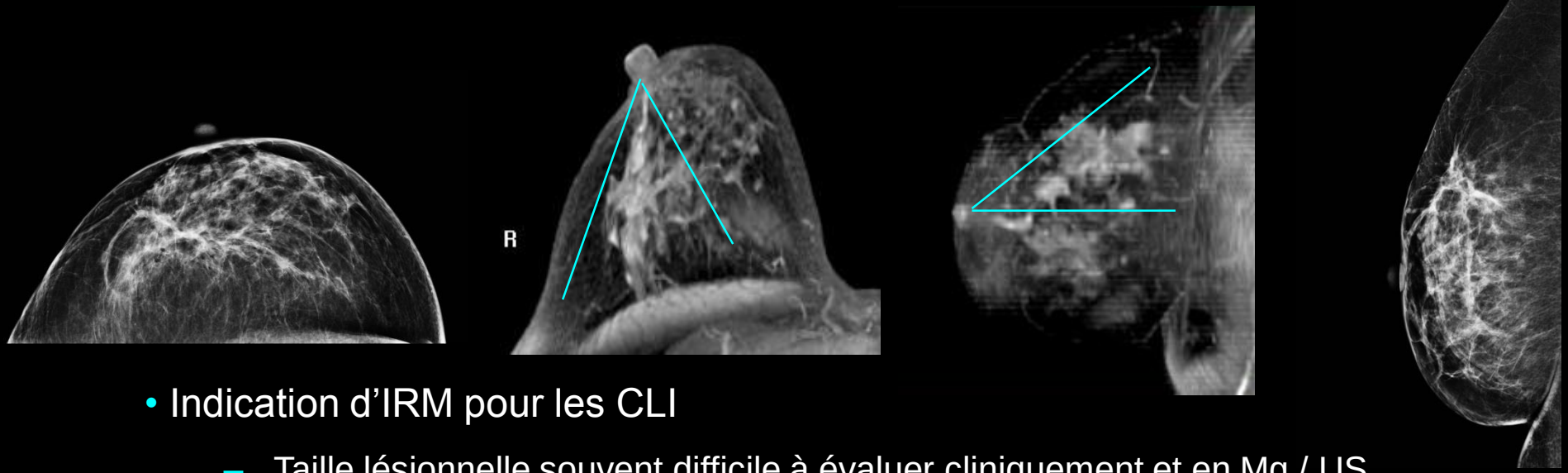

- Indication d'IRM pour les CLI
  - Taille lésionnelle souvent difficile à évaluer cliniquement et en Mg / US
  - Risque de multificalité et bilatéralité
- Lésion unique de grande taille

CLI Sein D

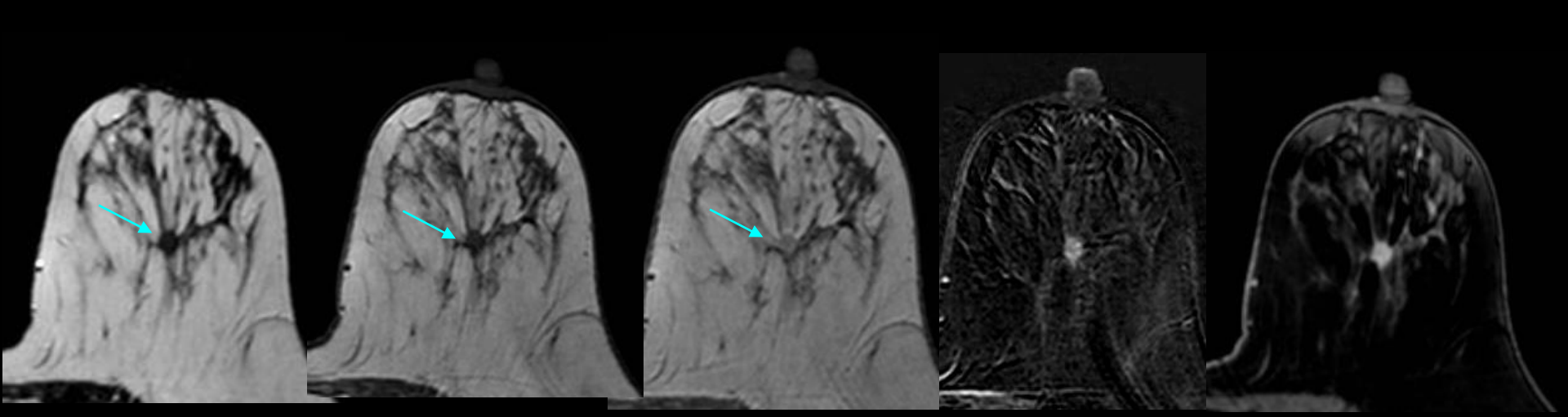

T2 | T1 sans injection | T1 après injection | Soustraction | Tardive injectée Fat Sat

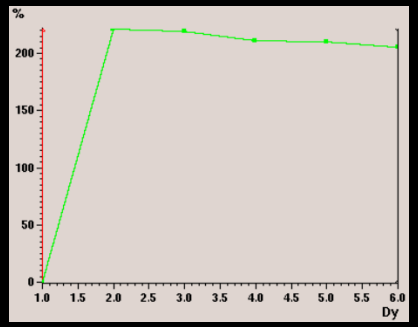

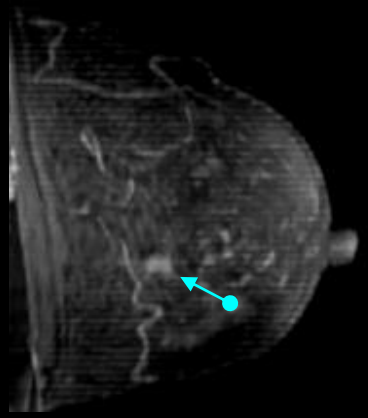

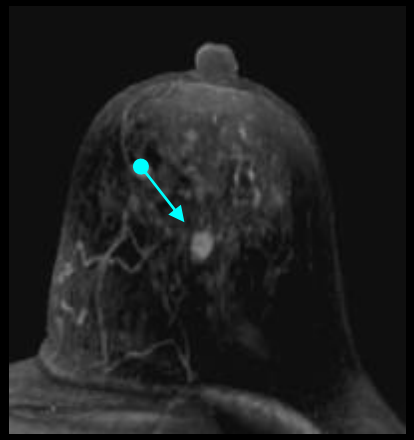

- Région centrale Sein G
  - Masse spiculée BIRADS 5
- Lésion unique de 7 mm

Sein G

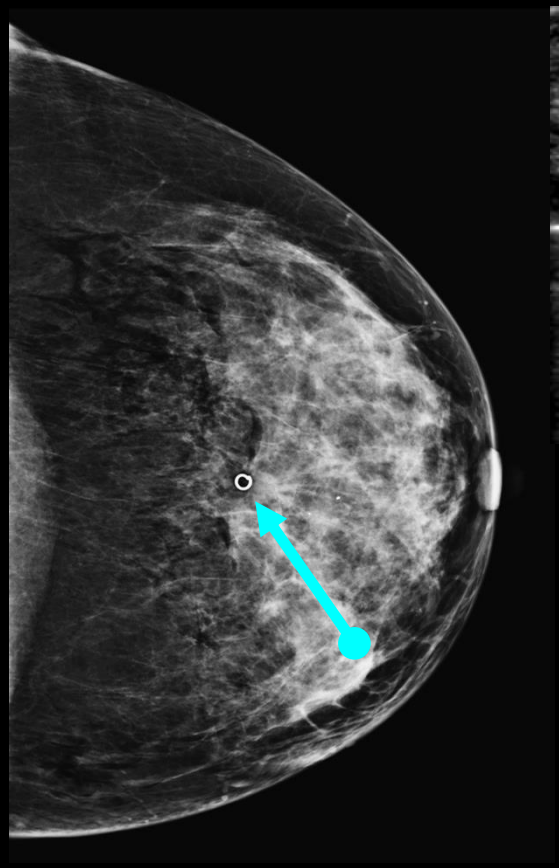

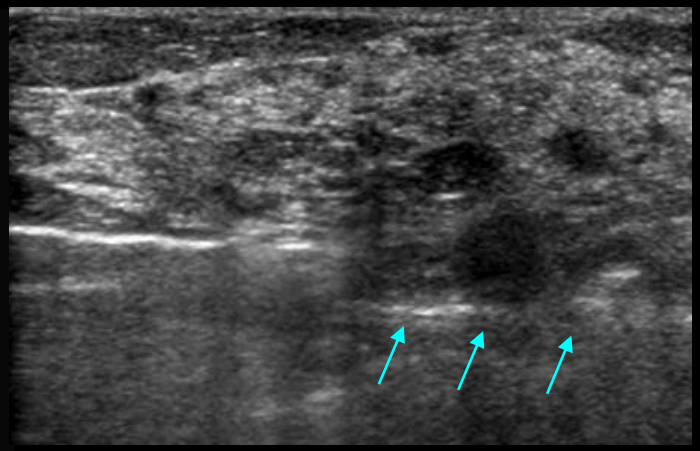

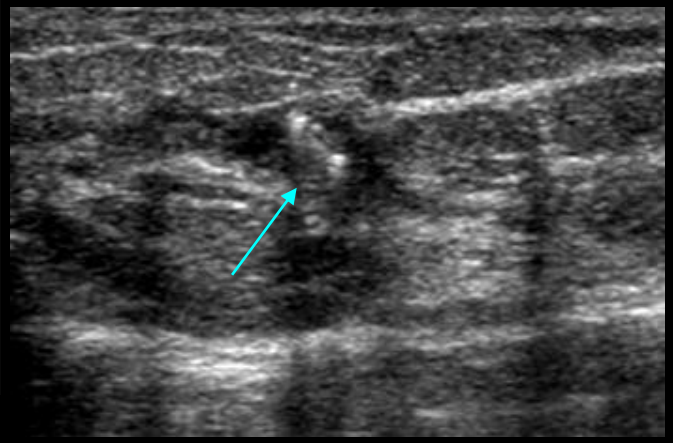

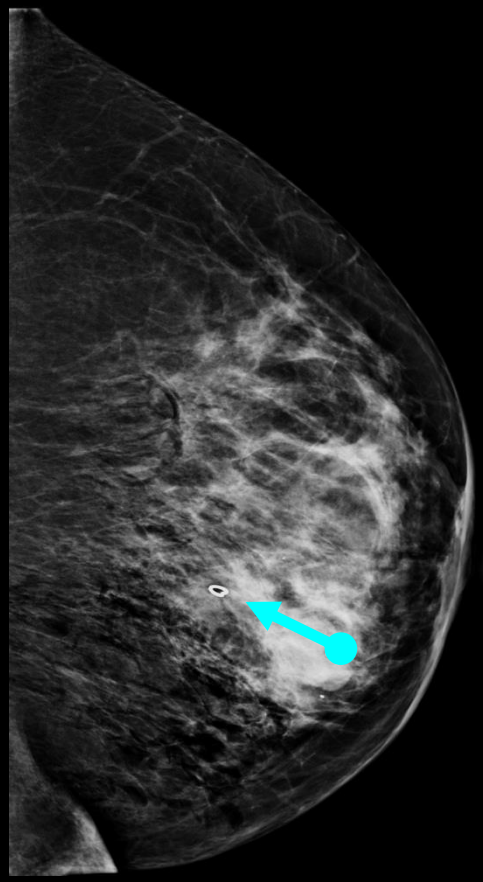

- Macrobiopsies sous échographie
- Pose de clip systématique : repérage pré-opératoire +++
- Histologie : CLI

- Discussion en réunion de concertation multidisciplinaire
  - Synthèse des examens d'imagerie
  - CAT thérapeutique

- Sein D
  - Discussion : Chirurgie (Quadrantectomie avec oncoplastie / MT), Traitement néoadjuvant
  - Décision MT avec CA

- Sein G
  - Tumorectomie (repérage sous écho) et GS

- Patiente de 55 ans – Mammographie systématique de dépistage

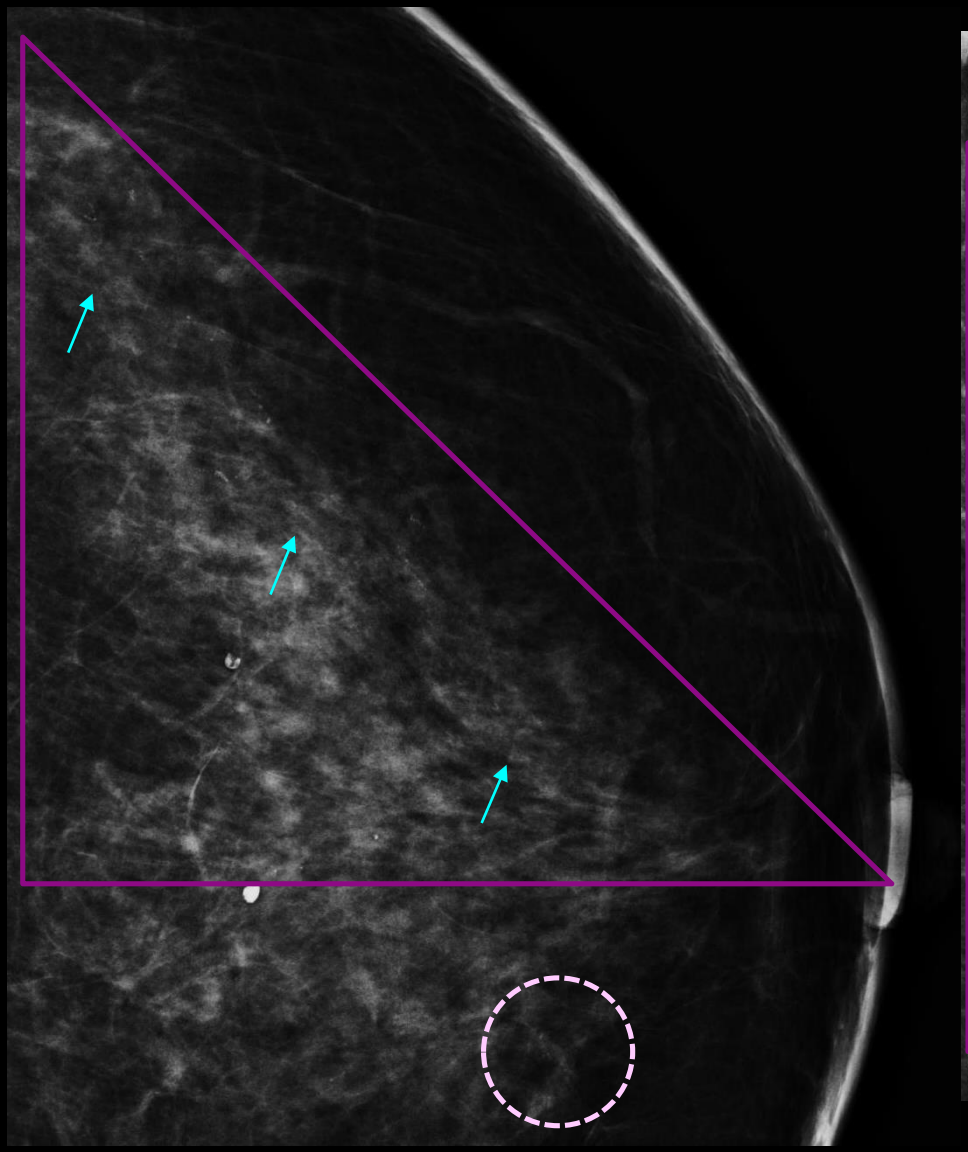

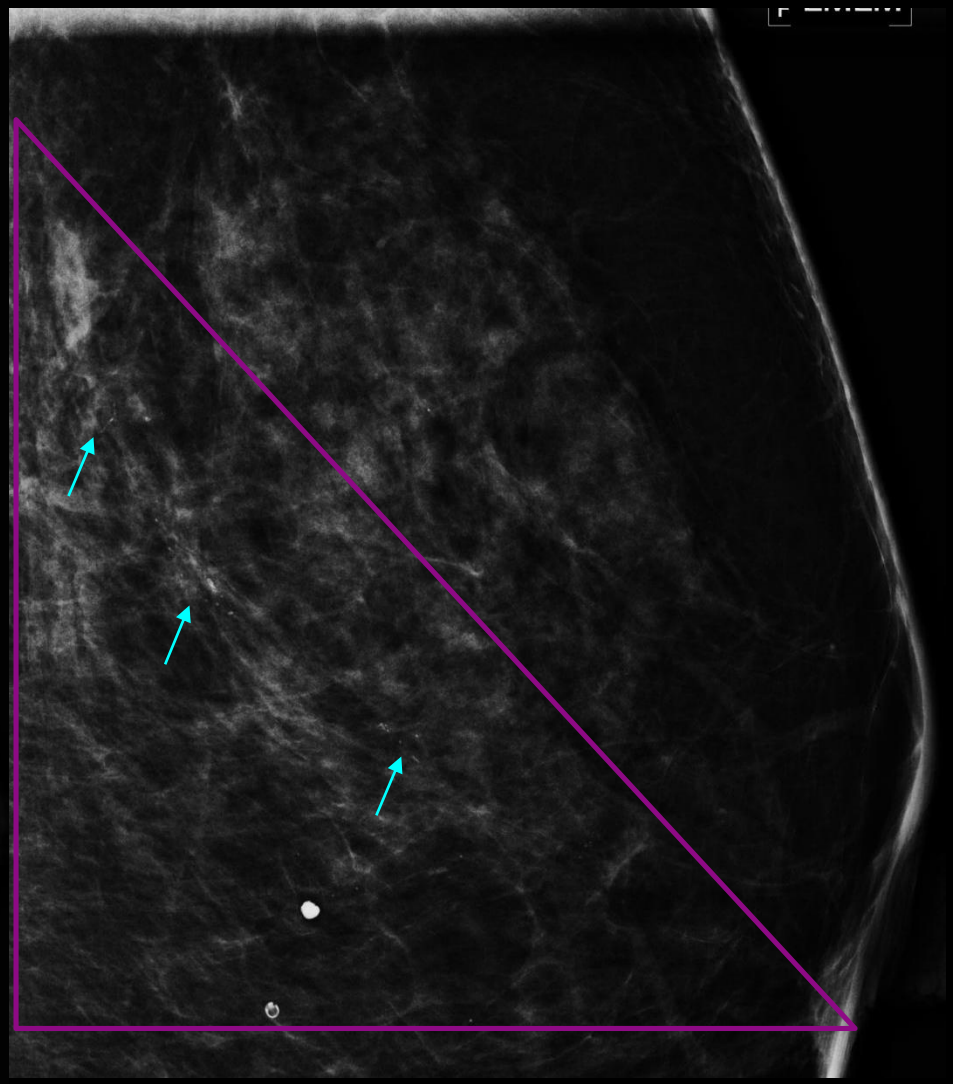

BIRADS 5

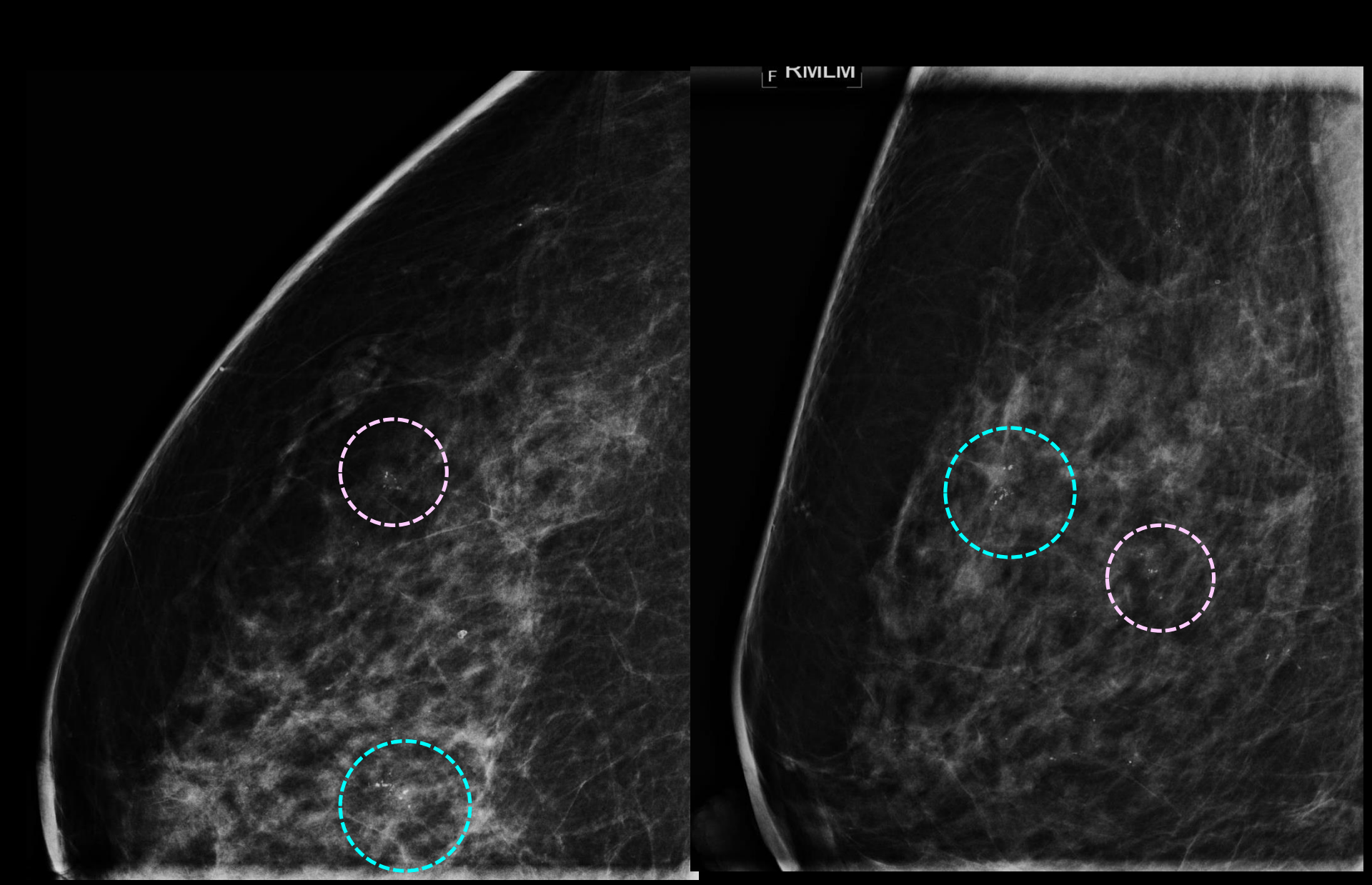

BIRADS 4

- Discussion du dossier en RCP avec le chirurgien
- Décision de macrobiopsies sous stéréotaxie bilatérales
- Sein G : microcalcifications étendues BIRADS 5
  - Discussion thérapeutique : MP / MT
  - 2 sites de prélèvements distants

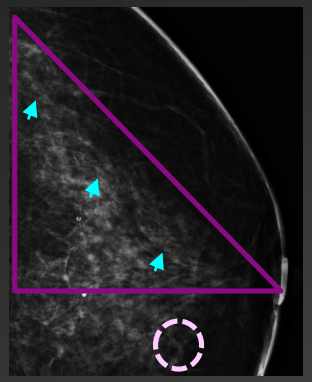

- Sein D : microcalcifications monomorphes BIRADS 4
  - 1 site de prélèvement (le plus représentatif)

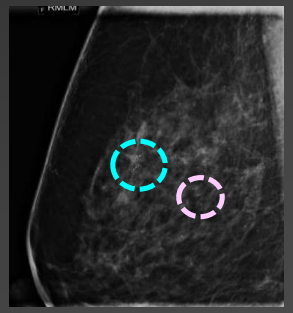

Macrobiopsies Sein G

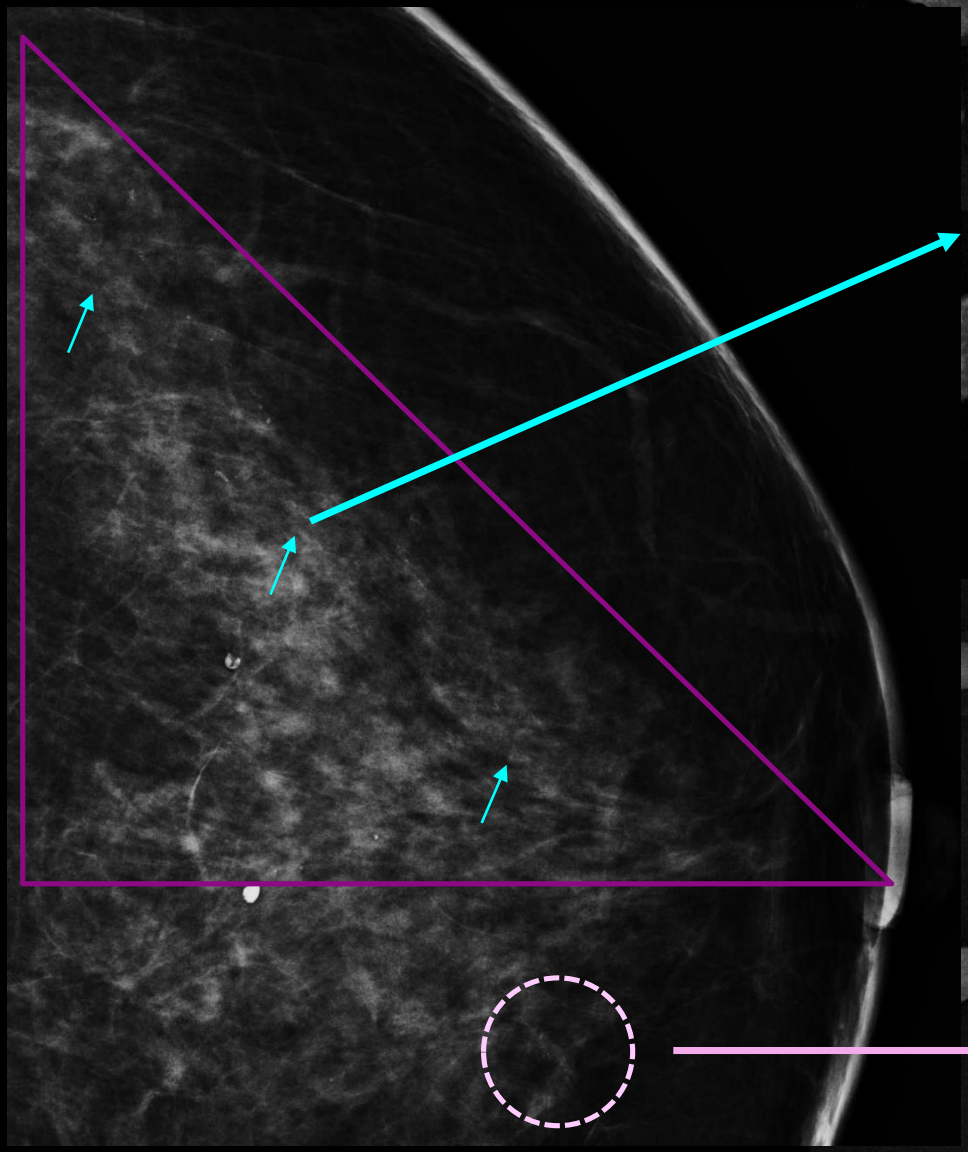

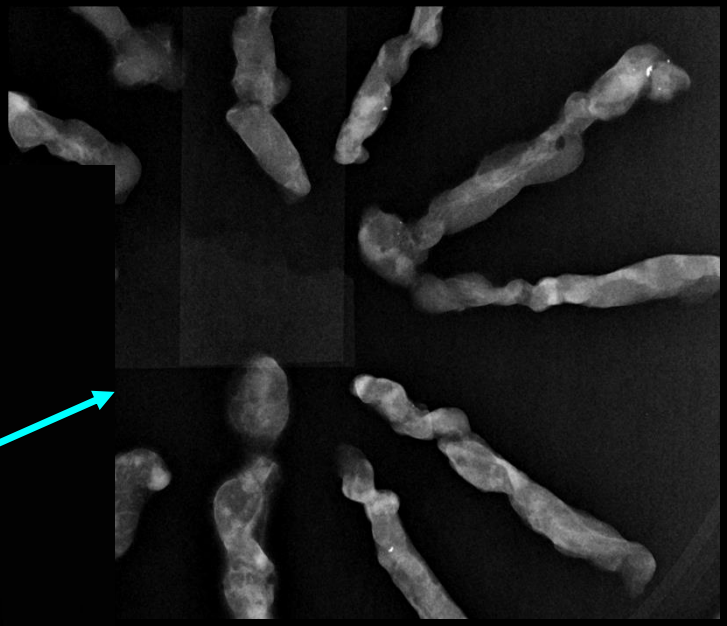

CCIS

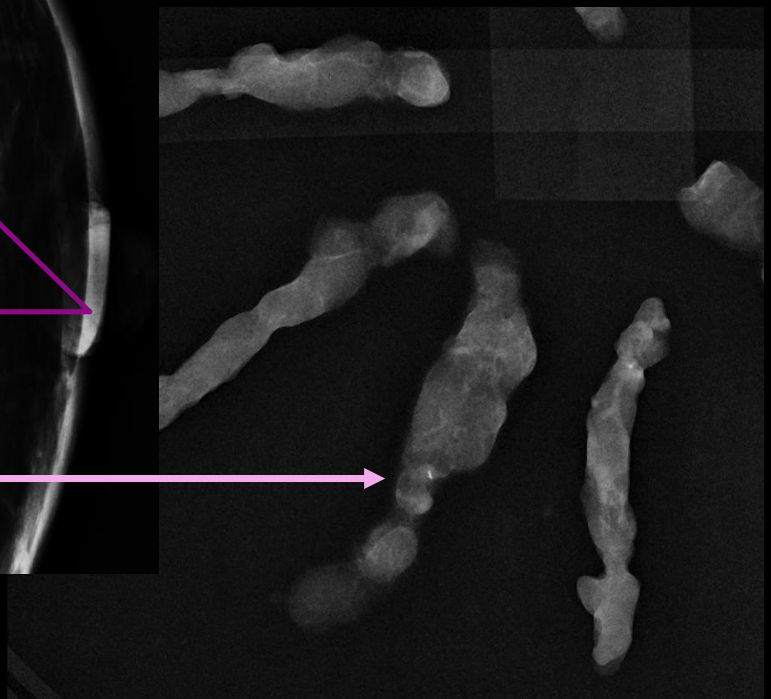

HCA

Post clip Sein G

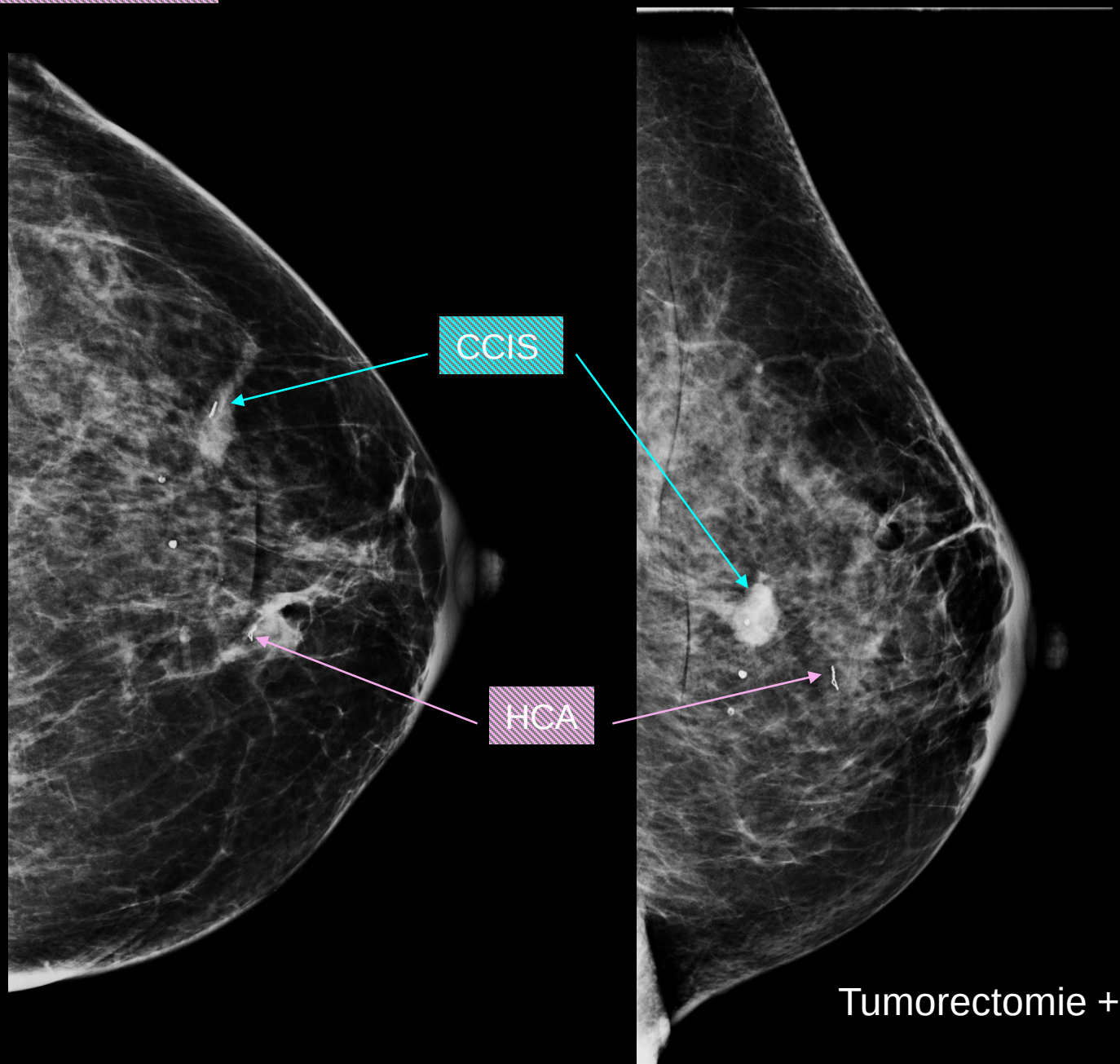

Tumorectomie + biopsie chir

Macrobiopsies Sein D

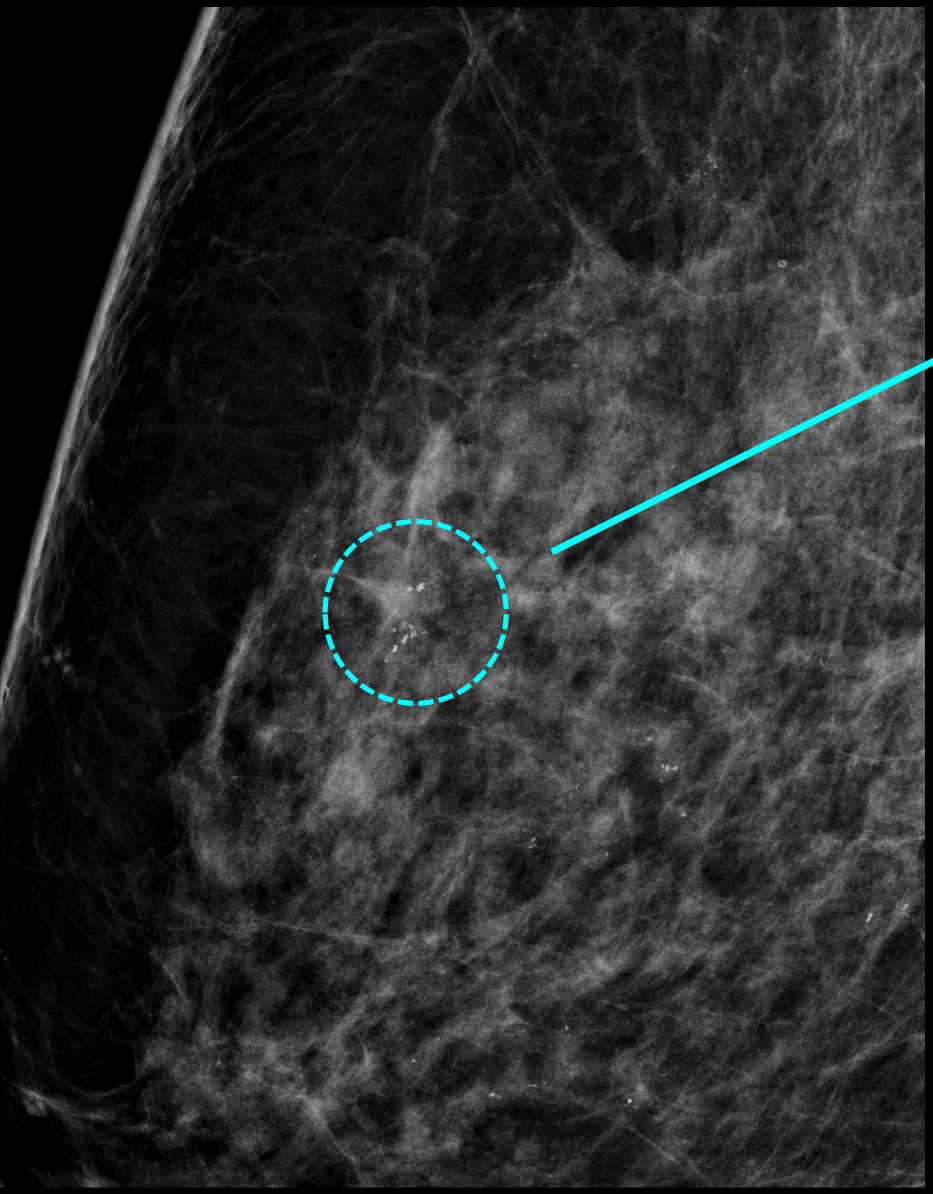

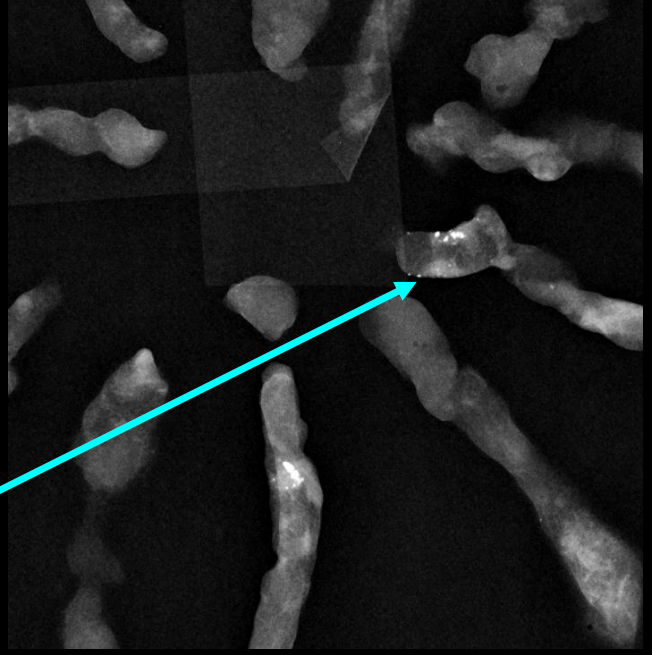

CCIS

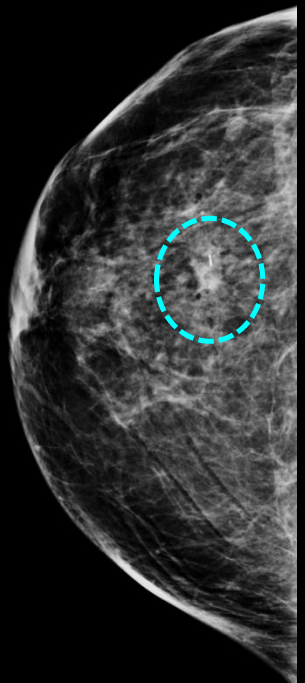

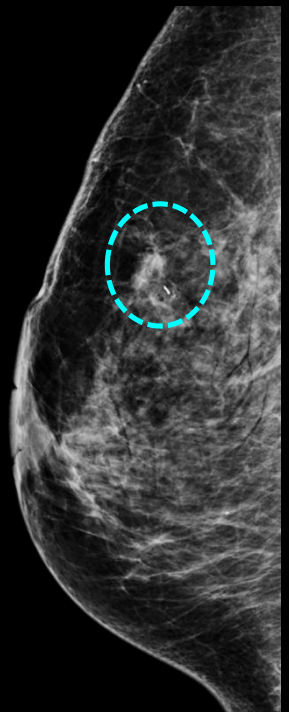

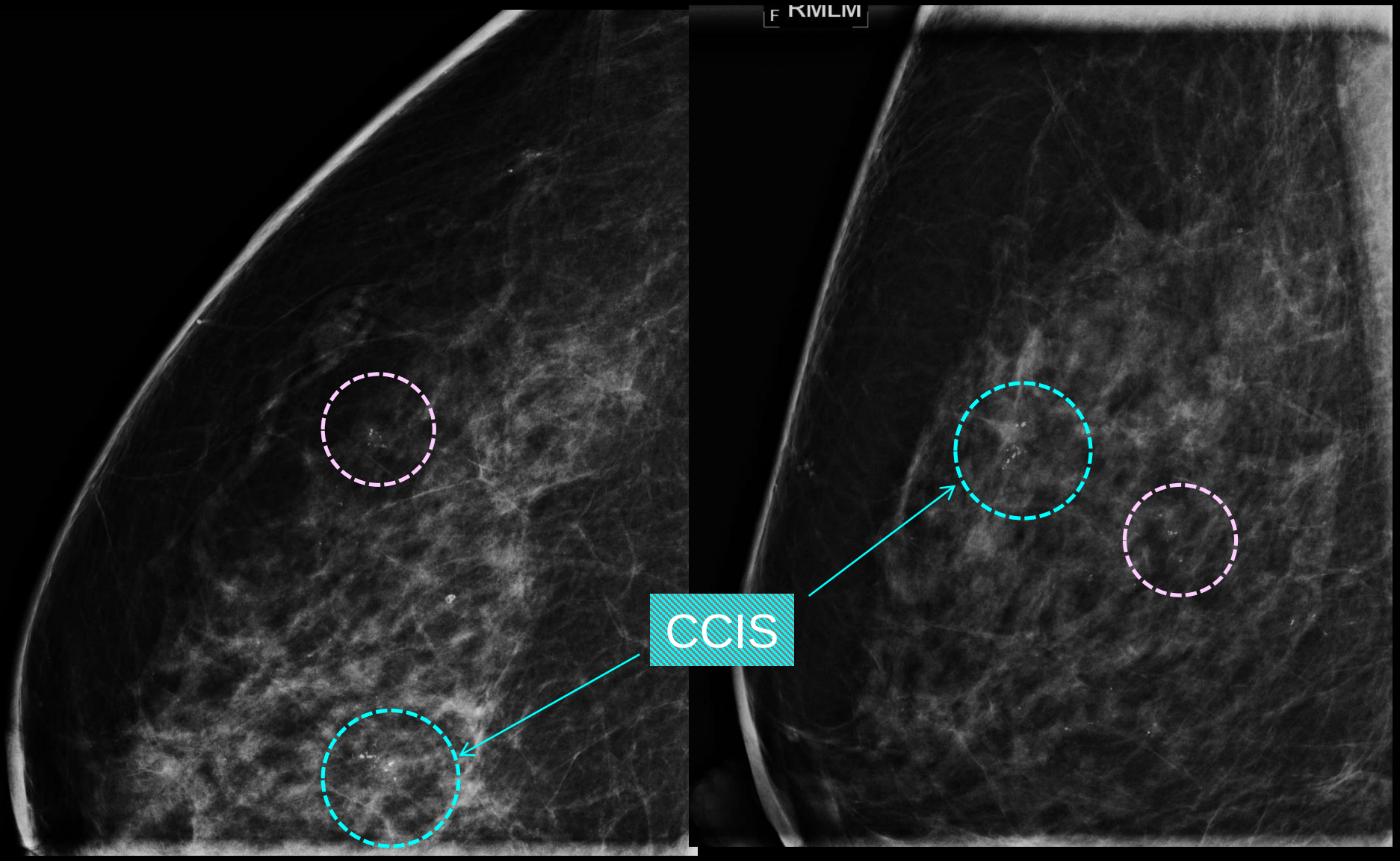

Discussion d'un double repérage post-opératoire ou d'un 2ième site de macrobiopsies sous stéréotaxie

Macrobiopsies Sein D

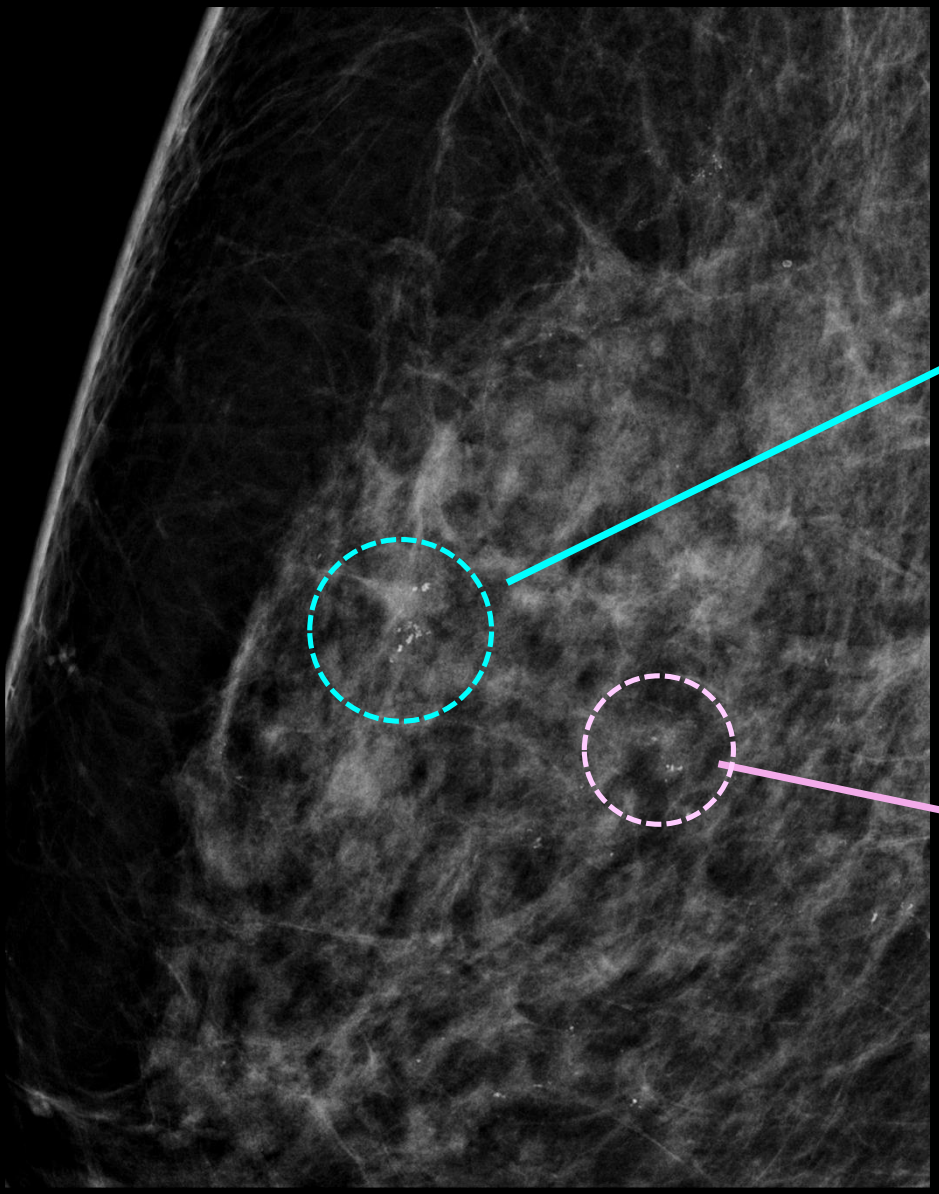

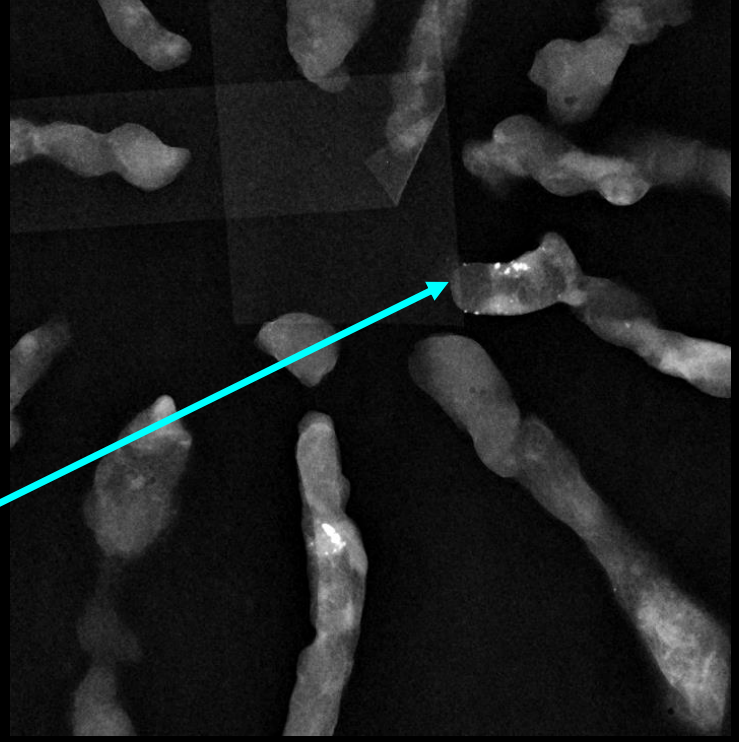

CCIS

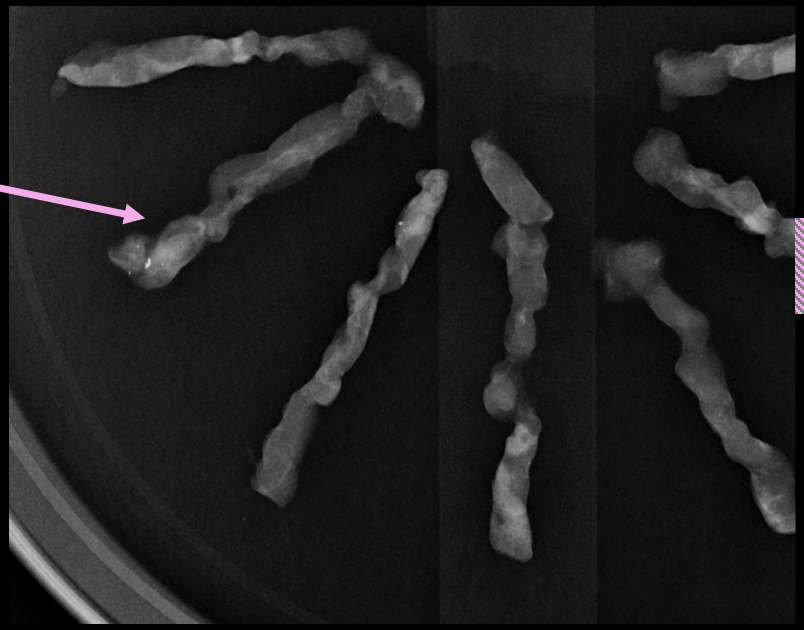

CCIS

Post clip Sein D

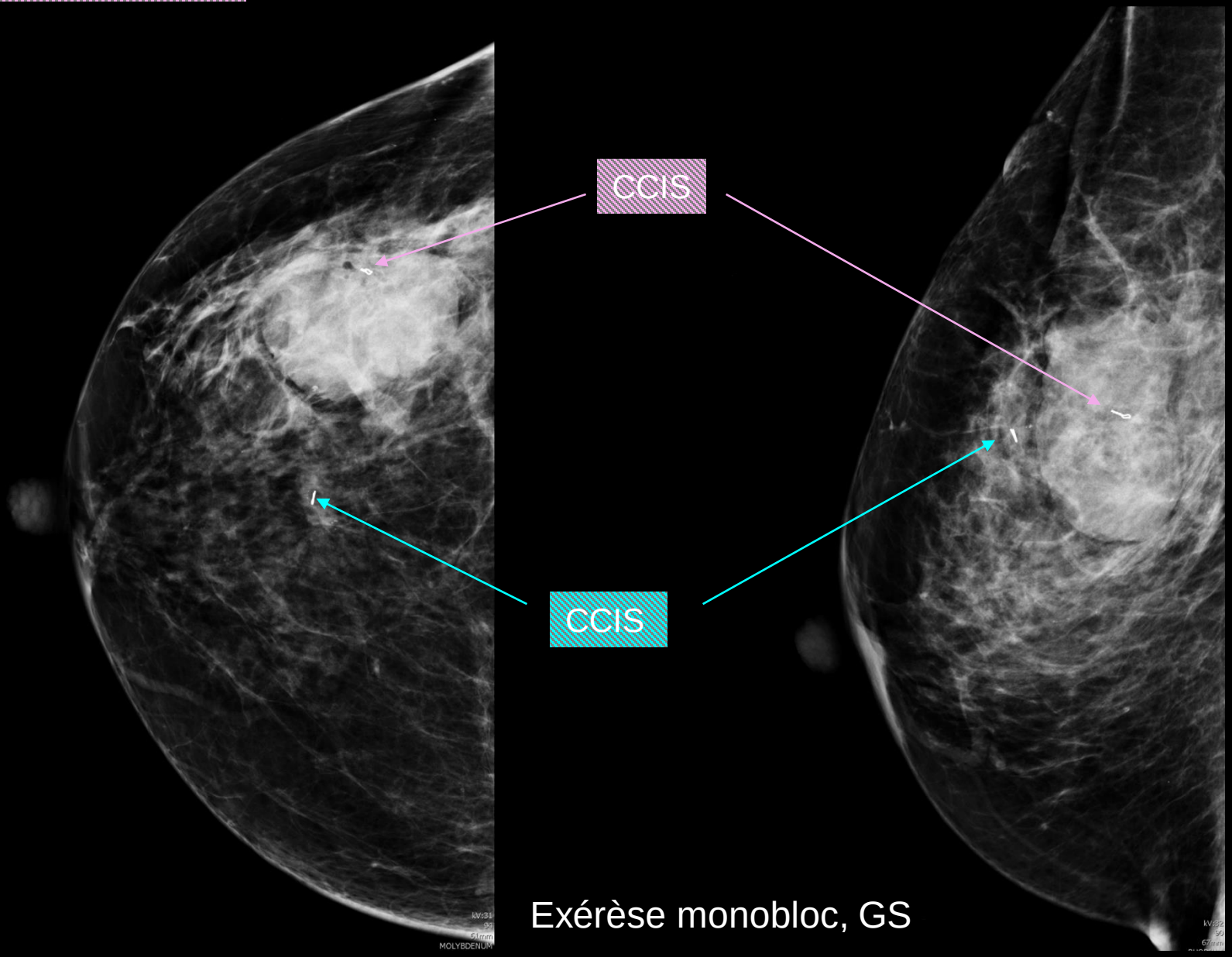

Exérèse monobloc, GS

- Patiente 67 ans sans ATCD
- Adressée pour biopsie d'une masse ACR 5 QIE sein D

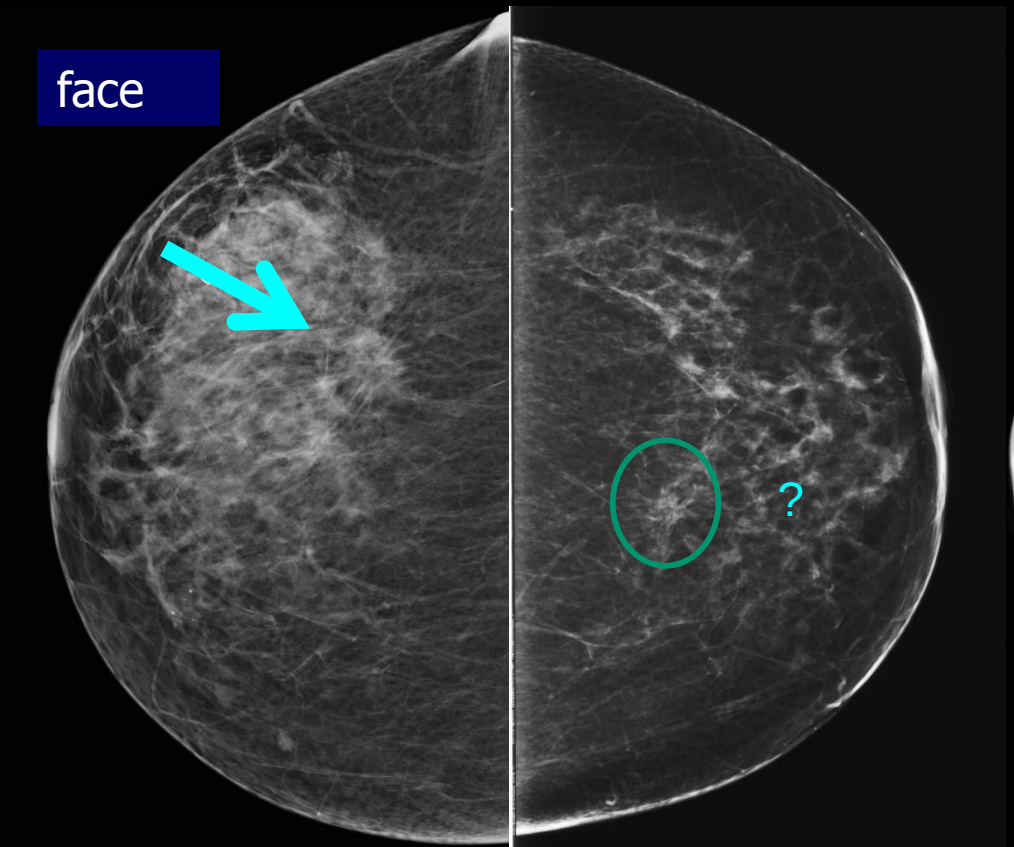

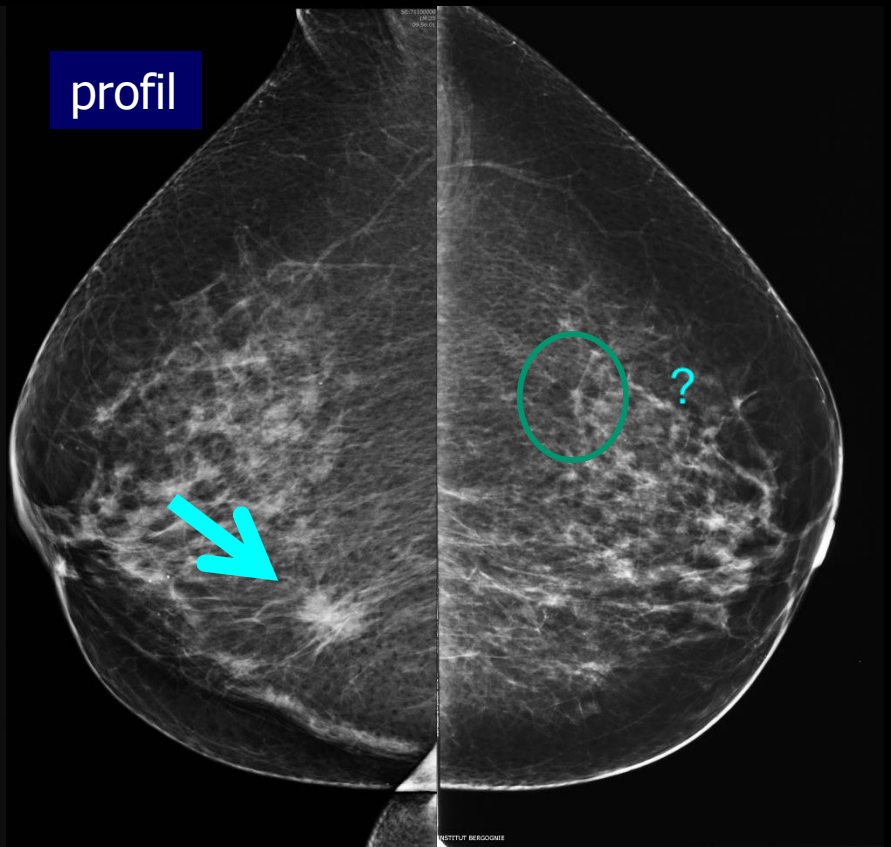

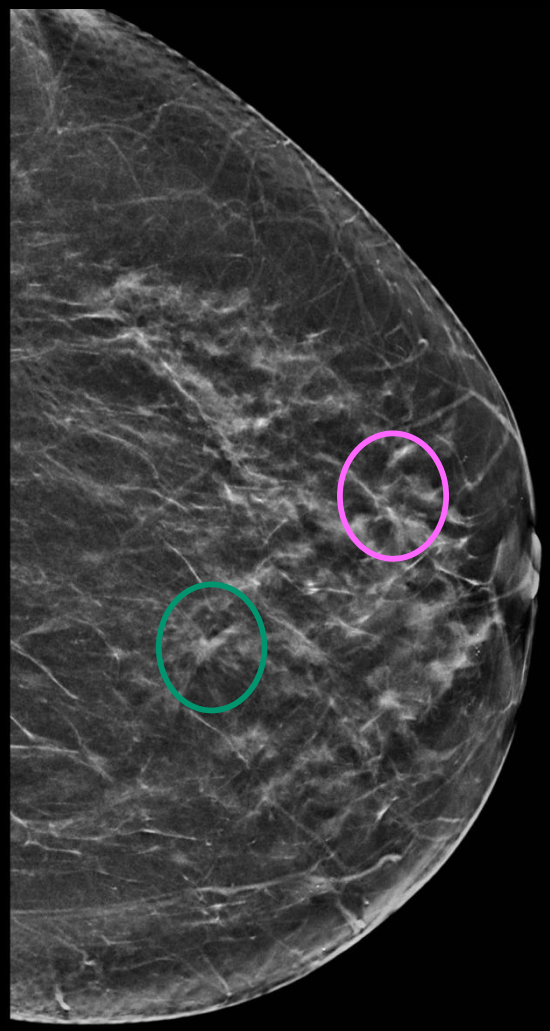

TOMO

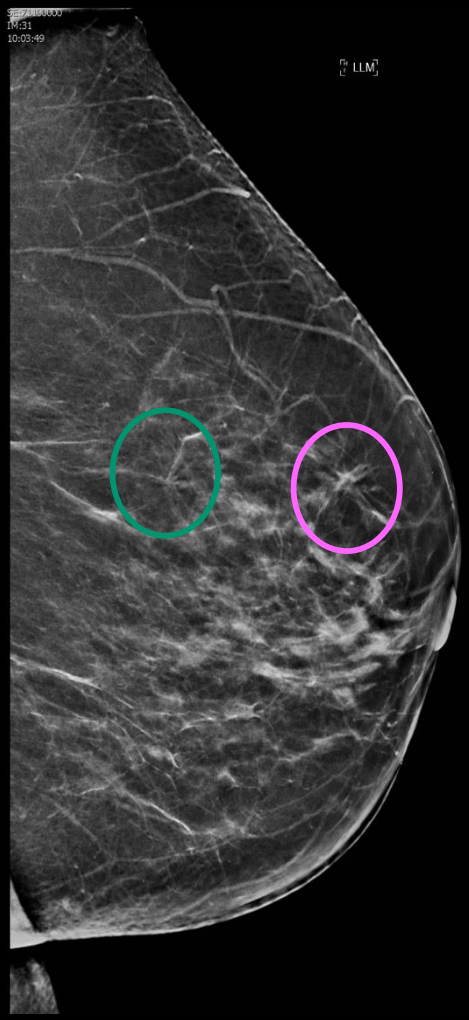

2 distorsions architecturales ACR 4 à gauche UQS et QSI
Indication de biopsies per-cutanées

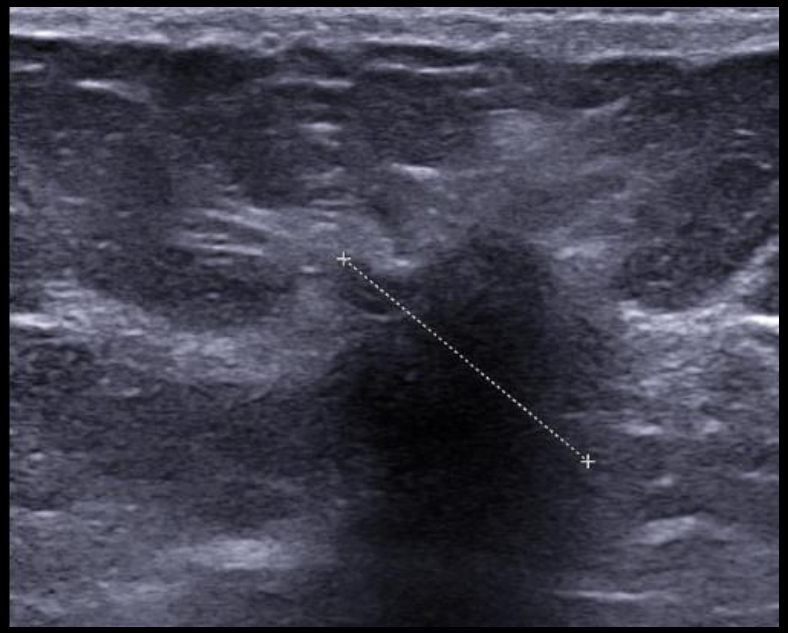

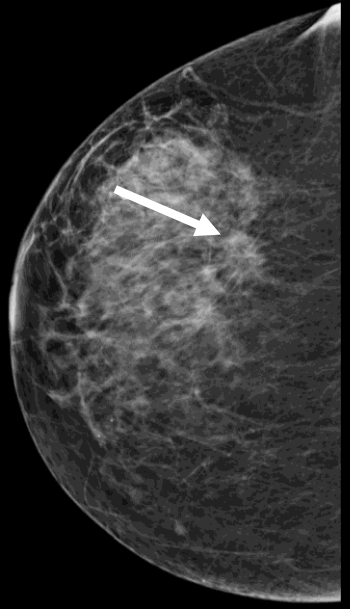

Sein D

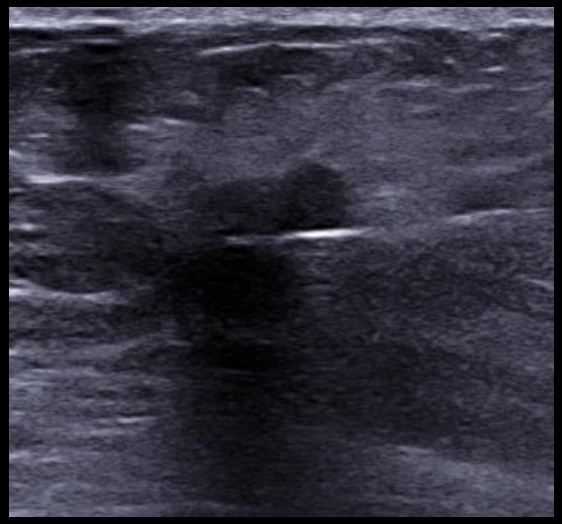

CLI gr 2

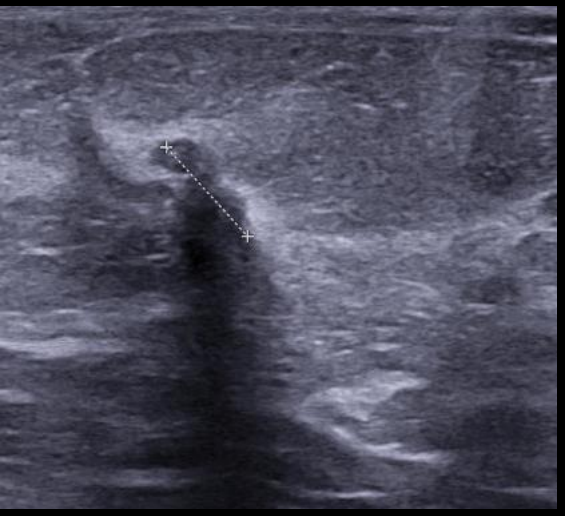

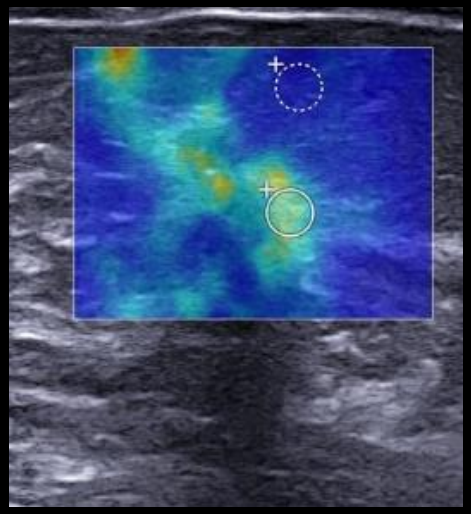

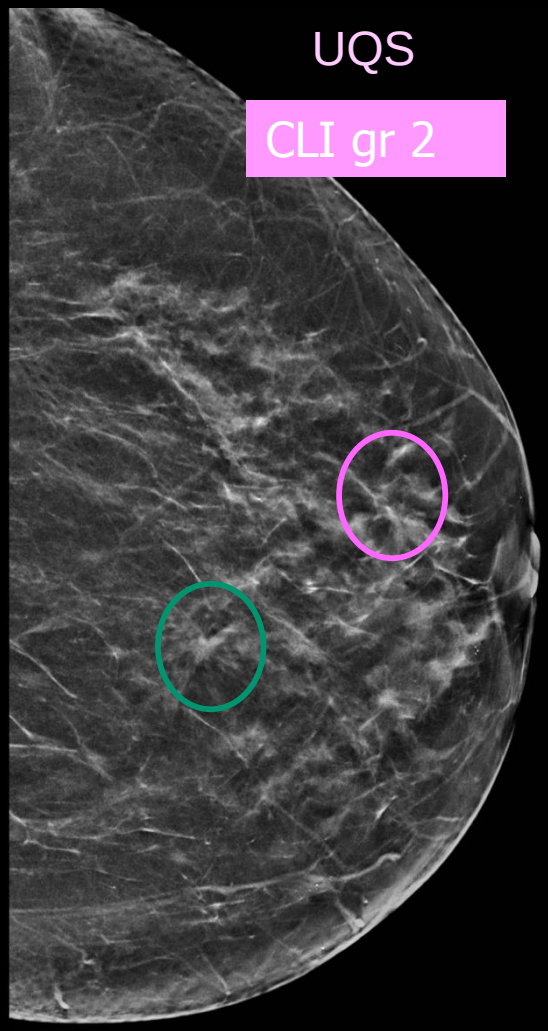

Pose de clip car lésion subtile : concordance Mg

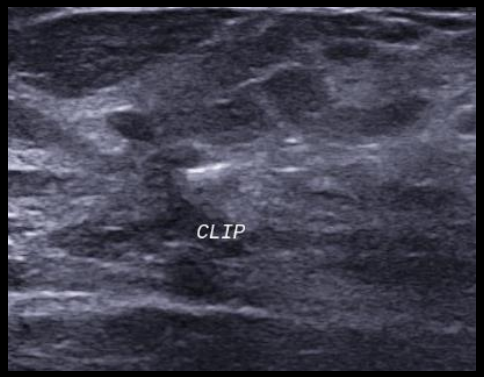

<u>Indication IRM</u>

- CLI, bilatéralité
- Dossier complexe

Macrobiopsies sous tomosynthèse + clip QSI

Lésion sclérosante complexe et CCIS

- **IRM complexe**
  - Masses spiculées de 17 et 10 mm QIE droit et UQS gauche : **CLI prouvés**

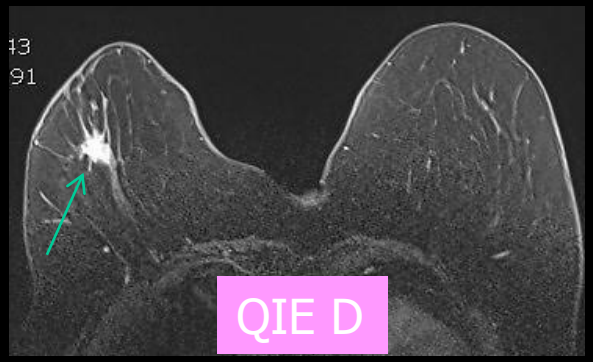

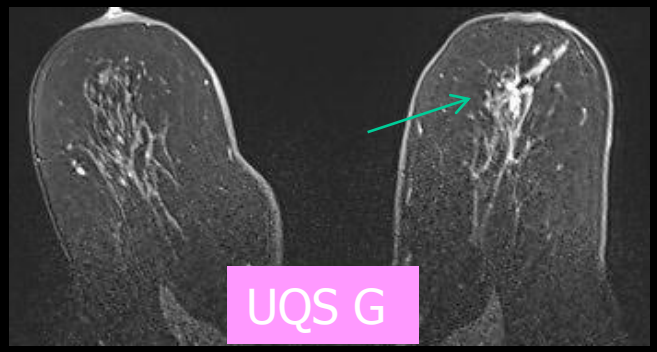

  - Masse spiculée de 9 mm QSI G correspondant à DA LSC + CCIS

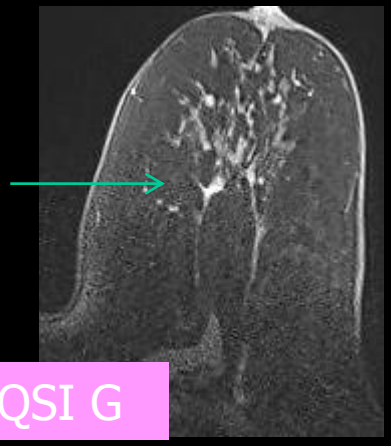

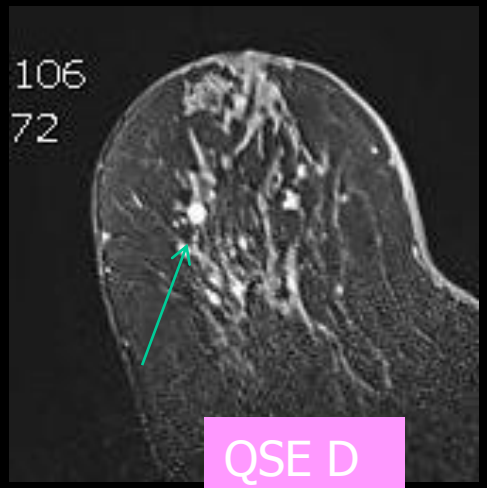

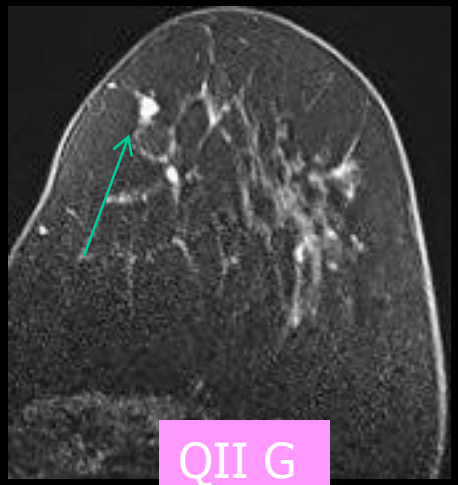

Multiples PDC à type de focci, zones focales et masses notamment

- Masse ACR 3 QSE droit
- Masse ACR 3 QII gauche

- Echographie de second look avec microbiopsies et pose de clips sur les masses ACR 3 QSE D et QII G car

- Modifie le geste chirurgical : indication potentielle de MT

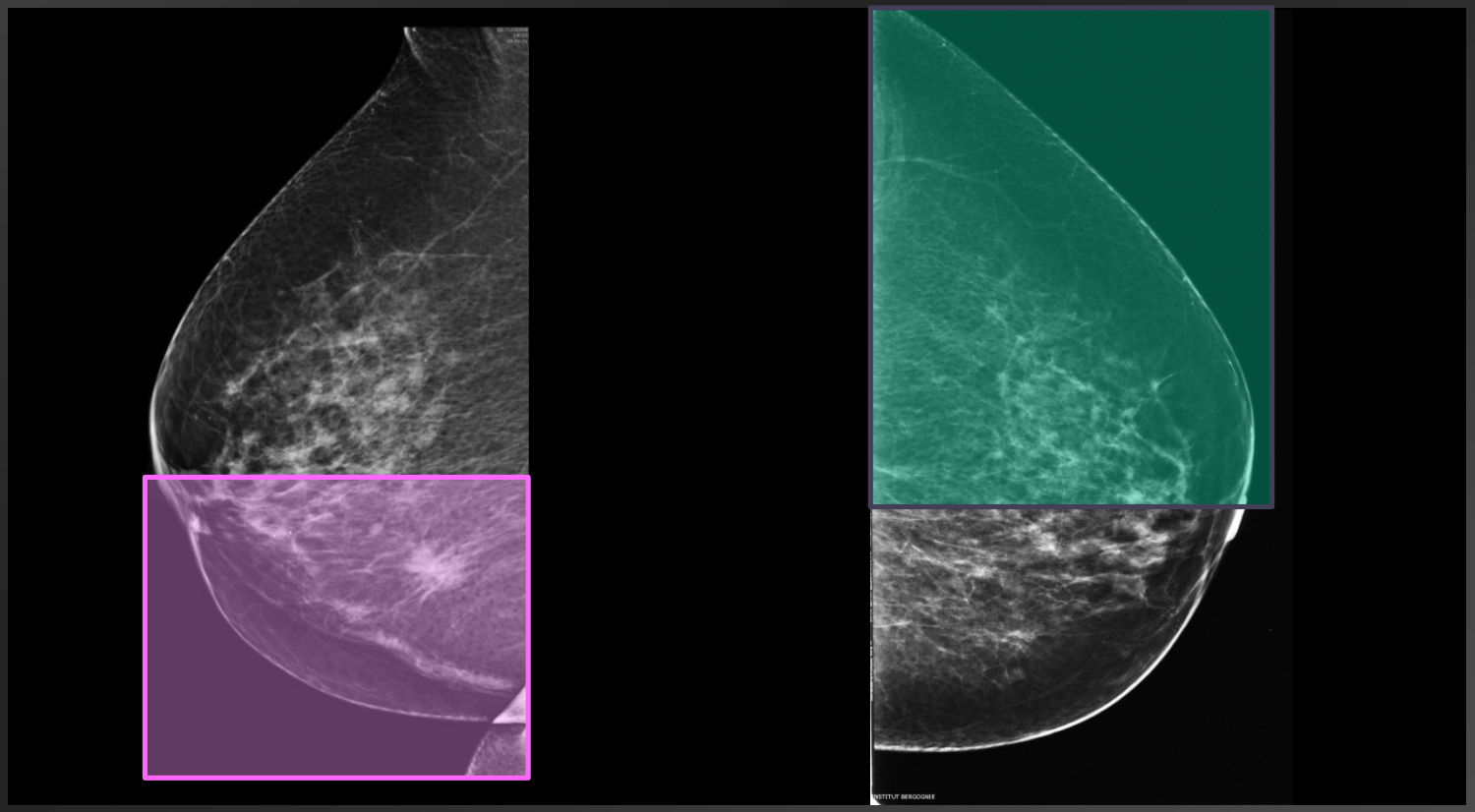

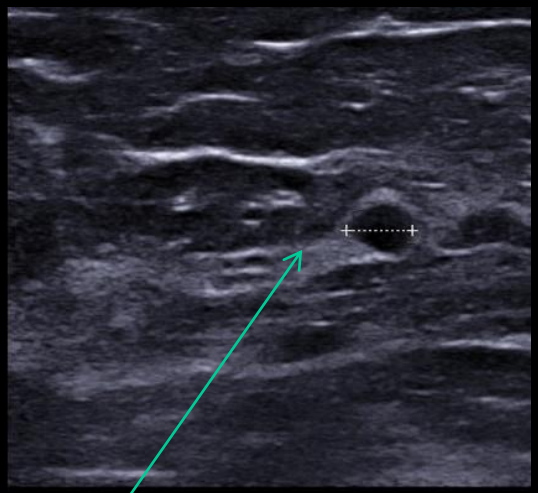

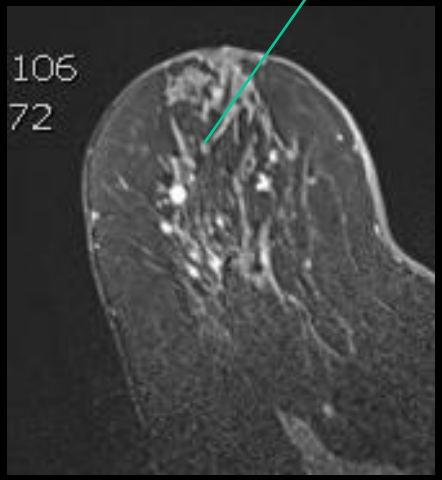

Double micros sous écho + clip

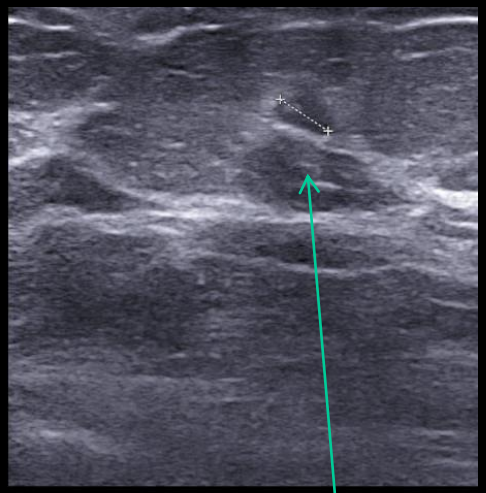

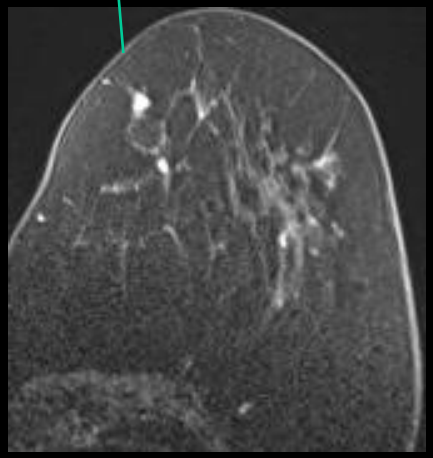

A droite: ADF
Bénin contributif

A gauche: papillo adénome
Lésion à risque

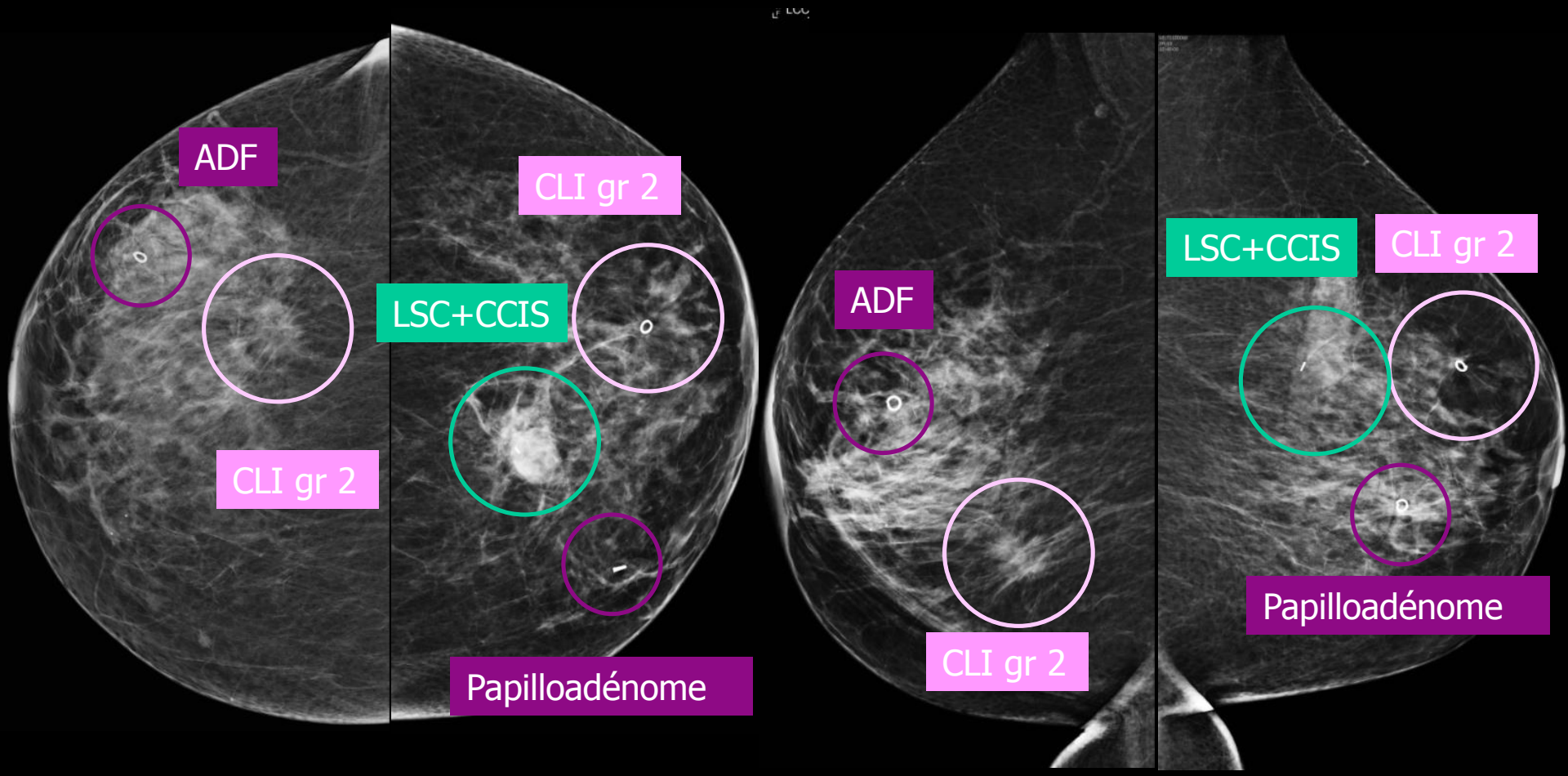

TTT conservateur bilatéral avec simple rep à D et triple rep à G

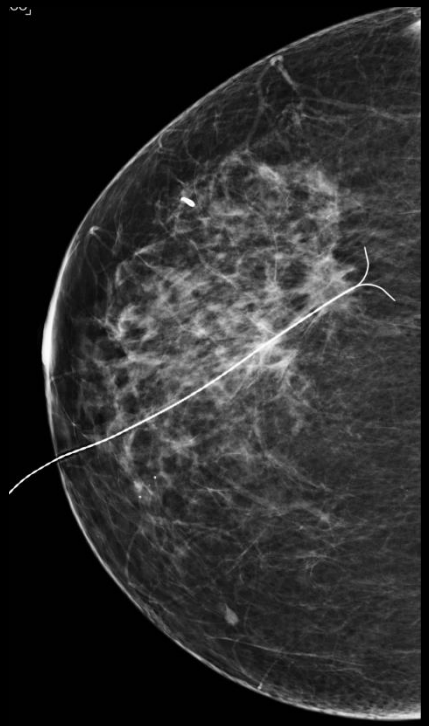

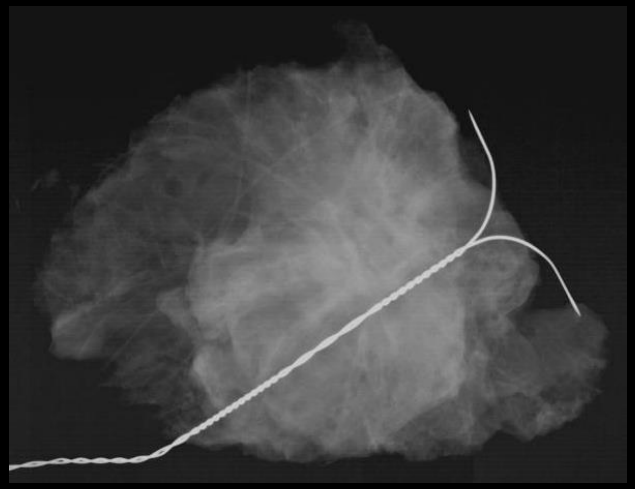

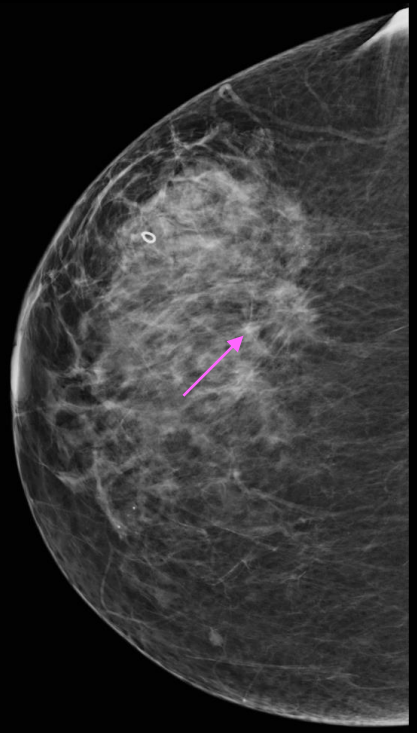

Sein D : **CLI gr 2 25 mm**

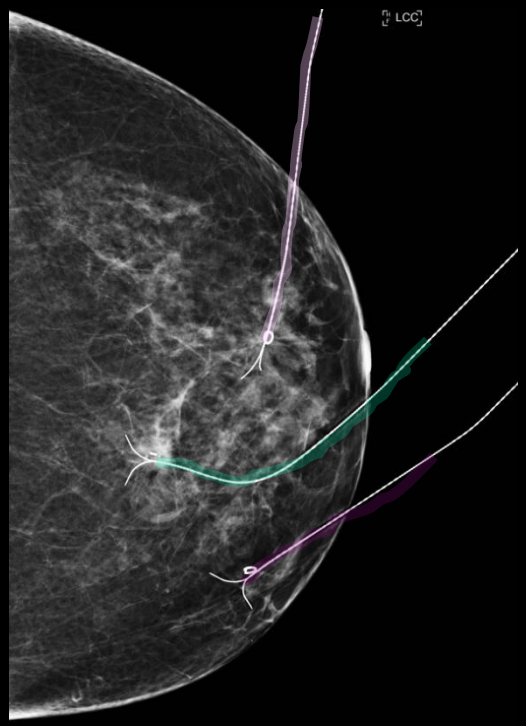

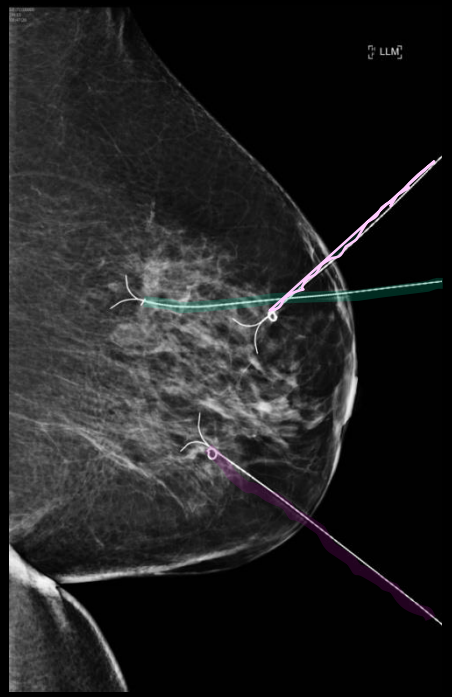

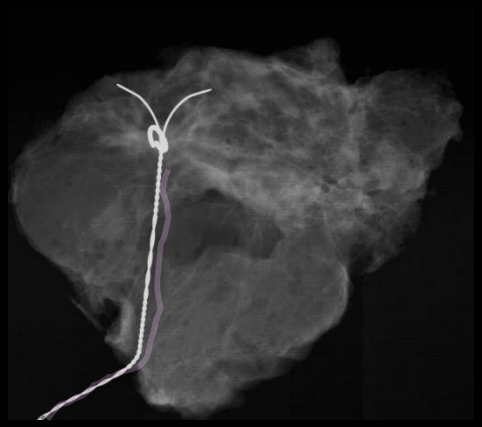

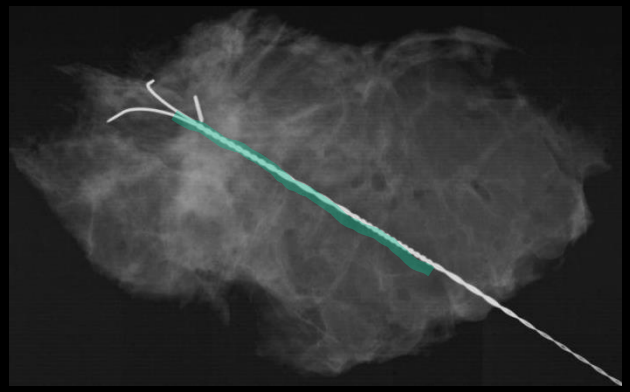

<u>Sein G</u> : UQS : CLI gr 2 de 9 mm

QSI : LSC + CCIS de 9 mm

QII : papilloadénome + LIN 2

- Rôle du radiologue : GPS du chirurgien
- **G**uider
  - Topographie précise
  - Taille lésionnelle, inter-lésionnelle, extension globale
  - Modalités du repérage préopératoire
- **P**rouver
  - Biopsies des lésions qui modifient la PEC avec bon compromis entre éloignement lésionnel et VPP de malignité
  - Clip +++ : concordance et choix thérapeutique
- Synthétiser
  - Nombre de lésions, taille, localisation et histologie
  - Schéma
- Importance de la communication radiologue - chirurgien